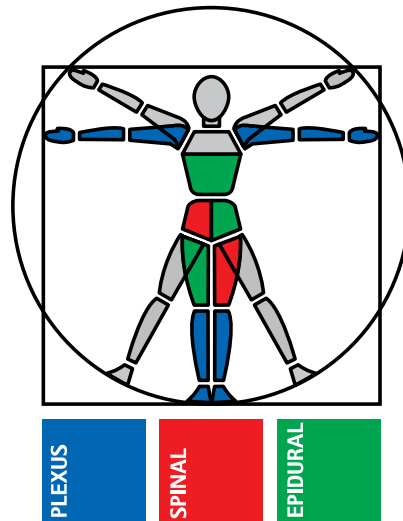


Paediatric Regional Anaesthesia: Stress-free surgery for your little Patient?

The Art of Regional Anaesthesia



Chairman: Dr. M. Rawicz, Poland

Including lectures presented by:

Dr. M. Jöhr, Switzerland

Prof. B. Dalens, France

Prof. G. Ivani, Italy

Already published:

- No. I Continuous Regional post-operative Analgesia:
Breaking up some Taboos
XVII. ESRA Congress, Geneva, September 1998
- No. II Plexus Anaesthesia and Today's Challenges
in Surgery and post-operative Pain Management
German Congress of Anaesthesiology,
Wiesbaden, May 1999
- No. III Review of Three Years Experience with the new
Spinocath® Continuous Spinal Anaesthesia (CSA)
system
XVIII. ESRA Congress Istanbul, September 1999
- No. IV Peripheral Nerve Block Catheter Techniques
– how to do?
XIX. ESRA Congress Rome, September 2000

Paediatric caudals: Still in or already out?

Martin Jöhr

Institut für Anästhesie, Kantonsspital, CH-6000 Luzern 16

joehrmartin@bluewin.ch

Regional anaesthesia is increasingly used in paediatric patients (1); including neonates and small infants (2). However, paediatric patients represent only a small proportion of the total anaesthetic caseload, e.g., in France 12% (3), and the global experience is relatively limited, especially for neonates and small infants. The single most important technique for paediatric patients is caudal anaesthesia, and a large body of experience exists for this technique (4-7). Single-shot caudal block can be considered a safe technique (8).

Technical details

Caudal anaesthesia is easy to learn (9), much easier than lumbar epidural or even spinal anaesthesia in adults. Osseous landmarks can be reliably identified even in neonates and infants; this contributes to safe performance of the technique in all age groups.

After induction of general anaesthesia and placement of the usual monitors, a left lateral position is obtained with the patient's upper hip flexed at 90°, the lower one only 45° (Fig. 1).

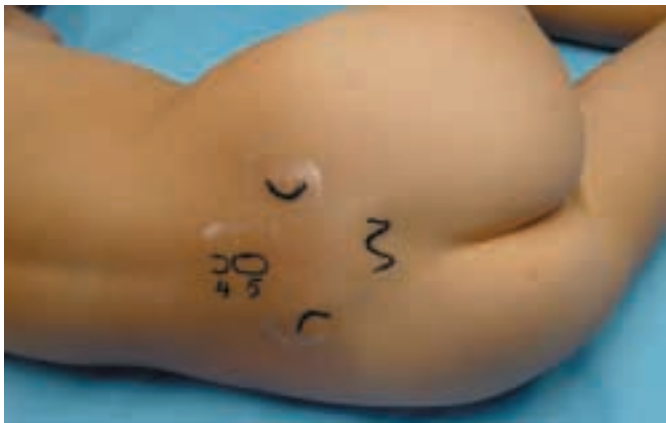

Fig. 1: A left lateral position is obtained with the patient's upper hip flexed at 90°, the lower one only 45°.

Before palpating the landmarks, the region is swabbed in a craniocaudal direction with alcohol solution to reduce the amount of bacteria. Extensive disinfection of the skin, sterile draping and wearing sterile gloves are now a universally accepted standard for all neuraxial blocks in adults. There is no reason to treat paediatric patients differently. Therefore, the so-called "no-touch technique" without gloves and sterile draping can no longer be advocated. Specially designed sets for paediatric caudal anaesthesia give optimal working conditions (Fig. 2).

Caudal epidural puncture is achieved in the most proximal region of the sacral hiatus and not between the sacral

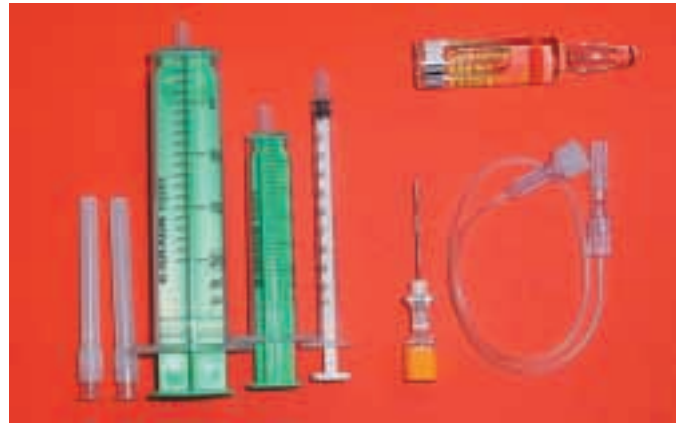

Fig. 2: Specially designed sets for paediatric caudal anaesthesia give optimal working conditions.

cornua; at that point the sacrococcygeal membrane is thickest and a clear "pop" or "give" can be felt. Furthermore, at that point the sacral canal is larger, making too deep needle insertion with intraosseous injection less likely (10). The index finger of the palpating left hand lies on spinous process S4 while the right hand advances the needle inclined 45°–60° to the skin (Fig. 3). After feeling the give of passing the sacrococcygeal membrane, the needle should only be minimally advanced, no more than 1 to 3 mm, to avoid vascular puncture or intrathecal injection (10). The use of extension tubing for an immobile needle technique is recommended. The injection of air to identify correct needle placement is no longer recommended, and may be associated with severe complications (11).

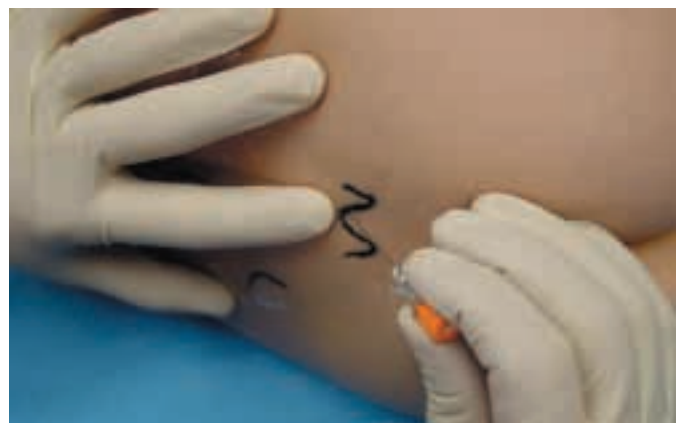

Fig. 3: The index finger of the palpating left hand lies on spinous process S4 while the right hand advances the needle inclined 45°–60° to the skin.

Different types of cannulae are currently in use. Although normal hypodermic needles have a long tradition and are still used by some colleagues (12), they are currently replaced by specially designed caudal needles with

a stylet and a relatively short bevel, as short-beveled needles have been shown to reduce the incidence of intravascular injections (6). In any case, it is the author's strong belief that the needle should not be larger than 25G, as small needles cause less trauma.

Drugs and dosage

The maximum recommended dose has to be calculated for every individual child. It is a rule of safety to draw up only the exact amount needed in order to avoid accidental overdose. It is generally accepted that for a single injection 2.5 mg/kg bupivacaine lies within safe limits, and 0.25 mg/kg/h is acceptable for continuous infusion (13). Restrictions probably have to be made for neonates and small infants because of the limited protein-binding in this age group (14). Slightly higher doses of ropivacaine can be used (15): 3-4 mg/kg for a single injection and 0.4 mg/kg/h for continuous infusion¹⁶.

Ropivacaine has been extensively studied in children; the 0.2% solution is well suited for paediatric caudal block. Ropivacaine has a similar duration of action compared to bupivacaine (17, 18), but causes less motor blockade (19), and in case of accidental intravascular injection probably less toxicity (20). Ropivacaine shows delayed absorption compared to plain bupivacaine (21); infants have higher plasma levels compared to older children (22), especially in the age group 1-3 months (23). A dosage of 1 ml/kg is well suited for inguinal incisions, and less is used for perineal procedures. Caudal anaesthesia is not recommended for inguinal incisions in children above 25 to 30 kg body weight, and a volume of over 30 ml is rarely administered.

Caudal anaesthesia is occasionally used as the sole anaesthetic in ex-preterm infants for inguinal hernia repair. However, the required doses are high (24) and CNS-toxicity is regularly seen (25). In addition, the duration of the blockade is short in small infants (26).

Additives

An epinephrine-containing test-dose allows the detection of intravascular needle placement in cases with negative aspiration, and may therefore increase safety (7). Moderate doses of epinephrine reliably increase the heart rate and cause an impressive increase in T-wave amplitude in children under 6 years of age (27).

Clonidine 1-3 ug/kg prolongs the duration of analgesia (28, 29). Side effects rarely occur and are not of clinical relevance. However, clonidine should be used with caution in newborns and small infants (30, 31).

Morphine provides long-lasting analgesia (32). However, side effects such as respiratory depression (33), nausea and vomiting, urinary retention and pruritus can occur. The author uses morphine 75 ug/kg as a single injection for patients having extensive surgery with a bladder catheter and monitors these patients for at least 12 hours in the PICU. More lipophilic opioids such as fentanyl, sufentanil, pethidine, tramadol or diamorphine have no clinical advantage for single-shot injection.

Ketamine (28, 34) or S-ketamine (35, 36) provides long-lasting analgesia by a spinal mechanism (35), however, this drug is not yet ready for wide clinical use.

Risks and complications

Regional anaesthesia in the anaesthetised patient requires special attendance, but is an accepted procedure in paediatric patients (37). General anaesthesia suppresses the alarms: there is no pain in case of intraneural injection and convulsions are absent after erroneous intravascular injection. In the case of caudal anaesthesia, the injection is made at a substantial distance from relevant neural structures, which makes it the method of first choice in the anaesthetised child. Gunter reported a retrospective study of more than 150,000 caudal blocks without a single case of haematoma or abscess formation (5). The French-language-speaking Society of Paediatric Anaesthesia (ADARPEF) prospectively studied 12,111 caudal blocks without a single case of permanent damage (4). Single-shot caudal block is thus remarkably safe: all technical (38) or septic (39) complications have been reported with catheter techniques and not with single-shot injections.

Conclusions

Caudal anaesthesia is the single most important technique for the paediatric patient population; extensive experience exists and specially-designed material is available. It is of outstanding importance in the concept of postoperative pain relief in children. However, it is part of a concept that also includes systemic medication such as nonsteroidals, paracetamol, and in some cases opioids.

Reference List:

- Jöhr M: *Kinderanästhesie*, 5. Auflage. München, Urban&Fischer, 2001
- de Lima J, Lloyd-Thomas AR, Howard RF, Sumner E, Quinn TM: Infant and neonatal pain: anaesthetists' perceptions and prescribing patterns. *BMJ* 1996; 313: 787-
- Clergue F, Auroy Y, Péquignot F, Jouglu E, Lienhart A, Laxenaire MC: French survey of anesthesia in 1996. *Anesthesiology* 1999; 91: 1509-20
- Giaufré E, Dalens B, Gombert A: Epidemiology and morbidity of regional anesthesia in children: a one-year prospective survey of the french-language society of pediatric anesthesiologists. *Anesth Analg* 1996; 83: 904-12
- Gunter, J. Caudal anesthesia in children: a survey. *Anesthesiology* 75, A936. 1991. Ref Type: Abstract
- Dalens B, Hasnaoui A: Caudal anesthesia in pediatric surgery: success rate and adverse effects in 750 consecutive patients. *Anesth. Analg.* 1989; 68: 83-9
- Veyckemans F, Van Obbergh LJ, Gouverneur JM: Lessons from 1100 pediatric caudal blocks in a teaching hospital. *Reg Anesth.* 1992; 17: 119-25
- Broadman L: *Complications of pediatric regional anesthesia, Complications of regional anesthesia*. Edited by Finucane BT. New York, Churchill Livingstone, 1999, pp 245-56
- Schuepfer G, Konrad C, Schmeck J, Poortmans G, Staffelbach B, Johr M: Generating a learning curve for pediatric caudal epidural blocks: an empirical evaluation of technical skills in novice and experienced anesthetists. *Reg Anesth Pain Med.* 2000; 25: 385-8
- Adewale L, Dearlove O, Wilson B, Hindle K, Robinson DN: The caudal canal in children: a study using magnetic resonance imaging. *Paediatr. Anaesth.* 2000; 10: 137-41
- Murat I: Anesthésie locorégionale chez l'enfant. Conférence d'experts (Congrès Sfar 1997). *Ann Fr Anesth Reanim.* 1997; 16: 985-1029
- Brown TCK, Eyres RL, McDougall RJ: Local and regional anaesthesia in children. *Br J Anaesth* 1999; 83: 65-77
- Berde CB: Convulsions associated with pediatric regional anesthesia. *Anesth Analg* 1992; 75: 164-6
- Mazoit JX, Denson DD, Samii K: Pharmacokinetics of bupivacaine following caudal anesthesia in infants. *Anesthesiology* 1988; 68: 387-91
- Morton NS: Ropivacaine in children [editorial]. *Br J Anaesth.* 2000; 85: 344-6
- Hansen TG, Ilett KF, Lim SI, Reid C, Hackett LP, Bergesio R: Pharmacokinetics and clinical efficacy of long-term epidural ropivacaine infusion in children. *Br J Anaesth.* 2000; 85: 347-53
- Ivani G, Lampugnani E, Torre M, Calevo MG, DeNegri P, Borrometi F, Messeri A, Calamandrei M, Lonnqvist PA, Morton NS: Comparison of ropivacaine with bupivacaine for paediatric caudal block. *Br J Anaesth* 1998; 81: 247-8
- Koinig H, Krenn CG, Glaser C, Marhofer P, Wildling E, Brunner M, Wallner T, Grabner C, Klimscha W, Semsroth M: The dose-response of caudal ropivacaine in children. *Anesthesiology* 1999; 90: 1339-44
- Da Conceicao MJ, Coelho L: Caudal anaesthesia with 0.375% ropivacaine or 0.375% bupivacaine in paediatric patients. *Br J Anaesth.* 1998; 80: 507-8
- Dony P, Dewinde V, Vanderick B, Cuignet O, Gautier P, Legrand E, Lavand'homme P, De Kock M: The comparative toxicity of ropivacaine and bupivacaine at equipotent doses in rats. *Anesth Analg* 2000; 91: 1489-92
- Ala-Kokko TI, Partanen A, Karinen J, Kiviluoma K, Alahuhta S: Pharmacokinetics of 0.2% ropivacaine and 0.2% bupivacaine following caudal blocks in children [In Process Citation]. *Acta Anaesthesiol Scand* 2000; 44: 1099-102
- Wulf H, Peters C, Behnke H: The pharmacokinetics of caudal ropivacaine 0.2% in children. A study of infants aged less than 1 year and toddlers aged 1-5 years undergoing inguinal hernia repair. *Anaesthesia* 2000; 55: 757-60
- Hansen TG, Ilett KF, Reid C, Lim SI, Hackett LP, Bergesio R: Caudal ropivacaine in infants: population pharmacokinetics and plasma concentrations. *Anesthesiology* 2001; 94: 579-84
- Bouchut JC, Dubois R, Foussat C, Moussa M, Diot N, Delafosse C, Claris O, Godard J: Evaluation of caudal anaesthesia performed in conscious ex-premature infants for inguinal herniotomies. *Paediatr. Anaesth.* 2001; 11: 55-8
- Breschan C, Hellstrand E, Likar R, Lonnqvist PA: Early signs of toxicity and "subtoxic" conditions in infant monitoring. Bupivacaine plasma levels following caudal anesthesia. *Anaesthesist* 1998; 47: 290-4
- Jöhr M, Seiler SJ, Berger TM: Caudal anesthesia with ropivacaine in an awake 1,090-g baby. *Anesthesiology* 2000; 93: 593
- Tanaka M, Nishikawa T: Evaluating T-wave amplitude as a guide for detecting intravascular injection of a test dose in anesthetized children. *Anesth Analg* 1999; 88: 754-8
- Cook B, Grubb DJ, Aldridge LA, Doyle E: Comparison of the effects of adrenaline, clonidine and ketamine on the duration of caudal analgesia produced by bupivacaine in children. *Br J Anaesth.* 1995; 75: 698-701
- Lee JJ, Rubin AP: Comparison of a bupivacaine-clonidine mixture with plain bupivacaine for caudal analgesia in children. *Br J Anaesth.* 1994; 72: 258-62
- Breschan C, Krumpolz R, Likar R, Kraschl R, Schalk HV: Can a dose of 2microg.kg(-1) caudal clonidine cause respiratory depression in neonates? *Paediatr Anaesth* 1999; 9: 81-3
- Bouchut JC, Dubois R, Godard J: Clonidine in preterm-infant caudal anesthesia may be responsible for postoperative apnea. *Reg Anesth Pain Med.* 2001; 26: 83-5
- Krane EJ, Jacobson LE, Lynn AM, Parrot C, Tyler DC: Caudal morphine for postoperative analgesia in children: a comparison with caudal bupivacaine and intravenous morphine. *Anesth Analg* 1987; 66: 647-53
- Karl HW, Tyler DC, Krane EJ: Respiratory depression after low-dose caudal morphine. *Can J Anaesth* 1996; 43: 1065-7
- Lee HM, Sanders GM: Caudal ropivacaine and ketamine for postoperative analgesia in children. *Anaesthesia* 2000; 55: 806-10
- Koinig H, Marhofer P, Krenn CG, Klimscha W, Wildling E, Erlacher W, Nikolic A, Turnheim K, Semsroth M: Analgesic effects of caudal and intramuscular S(+)-ketamine in children. *Anesthesiology* 2000; 93: 976-80
- Marhofer P, Krenn CG, Plochl W, Wallner T, Glaser C, Koinig H, Fleischmann E, Hochtl A, Semsroth M: S(+)-ketamine for caudal block in paediatric anaesthesia. *Br J Anaesth.* 2000; 84: 341-5
- Krane EJ, Dalens BJ, Murat I, Murrell D: The safety of epidurals placed during general anesthesia. *Reg Anesth Pain Med* 1998; 23: 433-8
- Lenox WC, Kost-Byerly S, Shipley R, Yaster M: Pediatric caudal epidural catheter sequestration: an unusual complication. *Anesthesiology* 1995; 83: 1112-4
- Emmanuel ER: Post-sacral extradural catheter abscess in a child. *Br J Anaesth* 1994; 73: 548-9

Peripheral blocks in children: Which techniques to begin with?

Bernard Dalens

Pavillon Gosselin

Hôtel-Dieu BP 69

F-63003 Clermont-Ferrand Cedex 1

France

During the last 20 years, the use of regional anaesthetic techniques in children has expanded considerably. Surprisingly, the first block procedures that were extensively used in paediatric patients were central blocks, namely caudal and epidural then spinal anaesthesia, i.e., the most dangerous techniques of regional anaesthesia. Only recently, peripheral nerve and compartment blocks have gained general acceptance due to their established safety and efficacy (1). However, few institutions are currently able to provide adequate teaching in these techniques and many anaesthesiologists of today who are willing to perform these techniques in their practice, are wondering which techniques they can use safely with limited training and experience, and which techniques they will be able to use with increasing experience in paediatric regional anaesthesia.

Infiltration techniques and compartment blocks

Infiltration techniques and compartment blocks are easy procedures that do not require particular skills, sophisticated devices or complicated location techniques. Their success depends on the identification of a fascial plane along which the local anaesthetic will spread to "fill" the compartment enclosed by this fascia and reach the nerve to be blocked. A short bevel (inexpensive) needle allowing easy identification of fascial plane (perception of a loss of resistance at the crossing of an aponeurosis) is the only device required and precise location of the nerve to be blocked is not necessary, even not mandatory, which avoids any possible traumatic damage. The failure rate of these infiltration techniques is extremely low provided they have been performed properly, i.e., the right fascial plane was clearly identified and traversed.

Peri-Umbilical or Rectus Sheath Block

Indications and contraindications: The peri-umbilical or rectus sheath block aims at providing complete analgesia of the peri-umbilical area (2, 3). The main indications are for providing pain relief during and after umbilical hernia repair. The technique can be adapted and used for the treatment of any hernia of the linea alba provided the injection is made at the level of the hernia. This block procedure has no true contraindications provided the rectus abdominis muscle is present and can be identified, which is obviously not the case in neonates with exomphalos or laparoschisis.

Anatomic Considerations: The umbilicus and umbilical area are supplied by the terminal branch of the 10th intercostal nerve of each side, after their emergence from the intercostal space, near the linea alba. At this level, the terminal branch crosses the deep aponeurosis of the rectus abdominis muscle, then traverses antero-posteriorly the substance of the muscle (supplying motor and sensory twigs) and, finally, crosses the superficial aponeurosis of the rectus muscle before it divides in several terminal subcutaneous branches supplying the skin surrounding the umbilicus.

The aponeurosis of the rectus muscle delineates a closed space where the nerve runs. Injecting a small amount of local anaesthetics within this space results in complete blockade of the ipsilateral terminal branch of the tenth intercostal nerve, thus providing anaesthesia to the umbilical area.

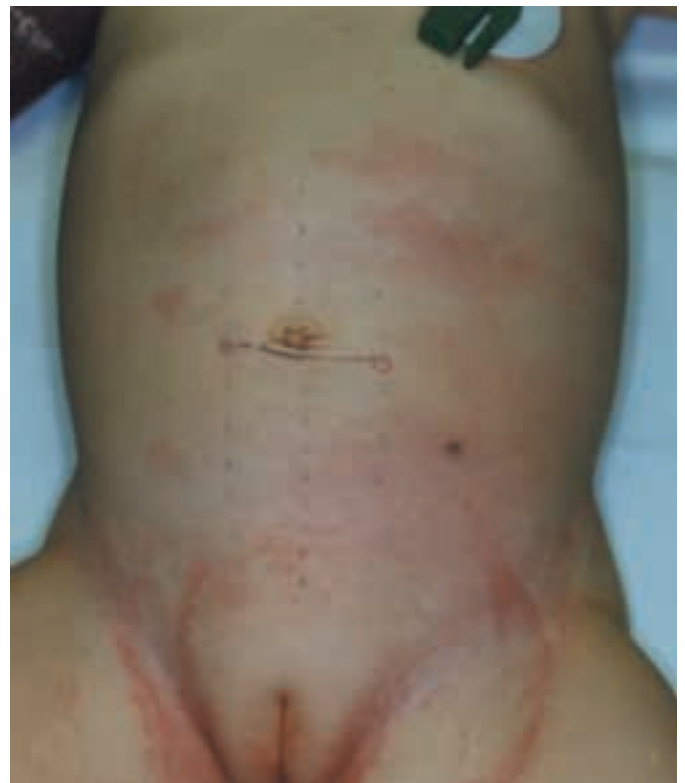

Figure 1: Rectus sheath/peri-umbilical block: landmarks
A: Landmarks

Technique: The patient is placed in the dorsal decubitus position. The landmarks are 1) the umbilicus, and 2) the lateral border of the rectus abdominis muscle of both sides, usually identifiable by palpation and sight. In chubby infants, this lateral border is often difficult to localise; in this case, a line drawn 2-3 cm lateral to the linea alba, on each side can be used instead. The site of puncture lies at the crossing of the outer border of the muscle with the horizontal line passing over the lower border of the umbilicus (Figure 1A). A short, short-bevelled needle is inserted obliquely through the skin, pointing to the upper border of the umbilicus at a 60° angle to the skin until it pierces (with some difficulty) the rectus sheath with a characteristic and often audible "click" (Figure 1B). The local anaesthetic is then injected in a fan shape manner at the upper, lateral and lower border of the umbilicus. An

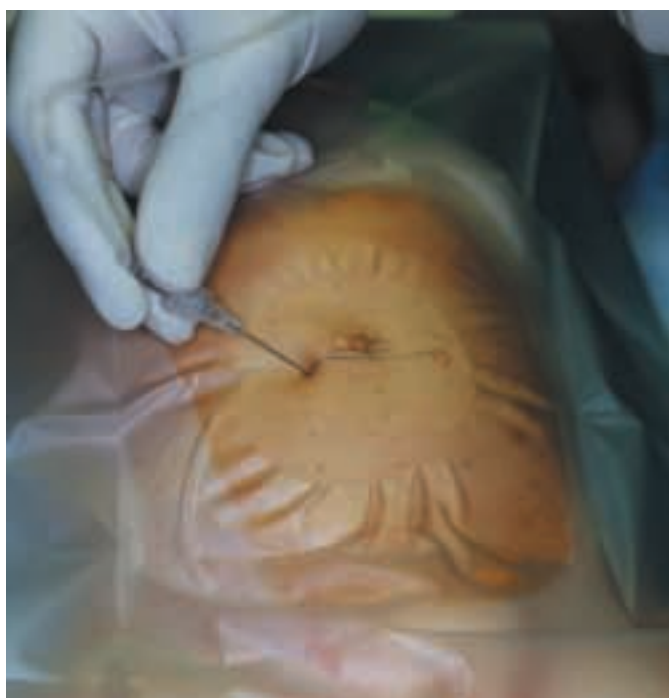

Figure 1: Rectus sheath/peri-umbilical block: landmarks
B: Insertion of the needle

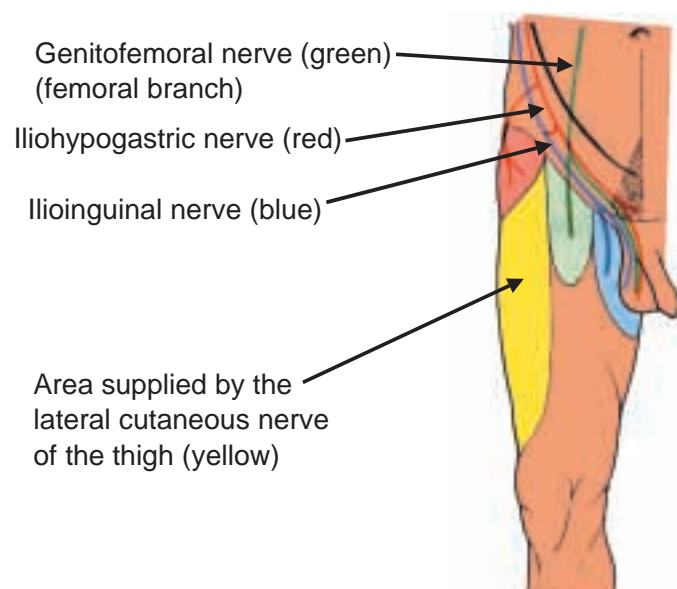


Figure 2: Ilioinguinal nerve block
A: Sensory supply provided by the ilioinguinal, iliohypogastric and genitofemoral nerve (from Anesthésie n°15, Braun France)

additional subcutaneous injection on withdrawal of the needle is recommended to still further improve the quality of analgesia (3). The same technique is repeated on the other side.

Long lasting local anaesthetics, i.e. 0.5% bupivacaine (with or without adrenaline) and 0.75-1% ropivacaine are preferred due to their long lasting effects (more than 6 hours of pain relief). A small volume (0.2 ml/kg per side) is sufficient to provide adequate analgesia. Addition of 1 µg/kg clonidine improves the quality of blockade and provides some sedation for 1-2 hours which allows quiet emergence from anaesthesia at the end of the surgery. The failure rate is extremely low.

This technique is very safe provided no sharp needle is used and introduced perpendicularly to the abdominal wall (which could result in intraperitoneal penetration of needle). When using a short-bevelled needle and following an insertion route at a 60° angle to the skin, the margin of safety is excellent as three resistant fascial planes (superficial, then deep aponeurosis of the rectus muscle, then peritoneum) have to be penetrated before the abdominal cavity is penetrated. When the technique is introduced in clinical practice, the surgeons often complain of some kind of "oedema" at skin incision but when they are used to it they usually consider this effect as advantageous because identification and dissection of the fascial planes is made easier.

Iliohypogastric And Ilioinguinal Nerve Blocks

Indications, contraindications and complications: Iliohypogastric-ilioinguinal nerve blocks (and block of the genital branch of the genitofemoral nerve) aim at providing complete analgesia of the ipsilateral inguinal area. The technique is recommended for most operations of the inguinal region (herniorrhaphy, orchidopexy, hydrocoele) including emergency procedures (incarcerated hernia with intestinal obstruction) (4). Due to its excellent risk/benefit ratio, the ilioinguinal and iliohypogastric nerve blocks tend to progressively replace caudal anaesthesia for surgery of the inguinal region.

The technique has no true contra-indication and the complication rate is extremely low. As for rectus sheath blocks, depending on the needle used and its orientation during the puncture technique, there is a potential danger of penetrating the abdominal cavity, a complication which was recently reported (5). Also, mostly depending on the volume injected and the anatomical particularities of the patient (6), undesired nerve block are not unusual, mainly femoral nerve block which may preclude discharge from hospital the same day (7,8). The total amount of local anaesthetic has to be considered carefully. In contradiction to previously published data (9), Smith et al. (10) reported a paediatric study involving 30 patients with unexpectedly high plasma bupivacaine concentrations (without clinical signs of toxicity) in the younger group of patients (weighing 10 to 15 kg), thus inciting the authors to recommend avoiding injection of more than 1.25 mg/kg of bupivacaine in infants. Ropivacaine might improve the safety of the block procedure (11) but available data are still scarce.

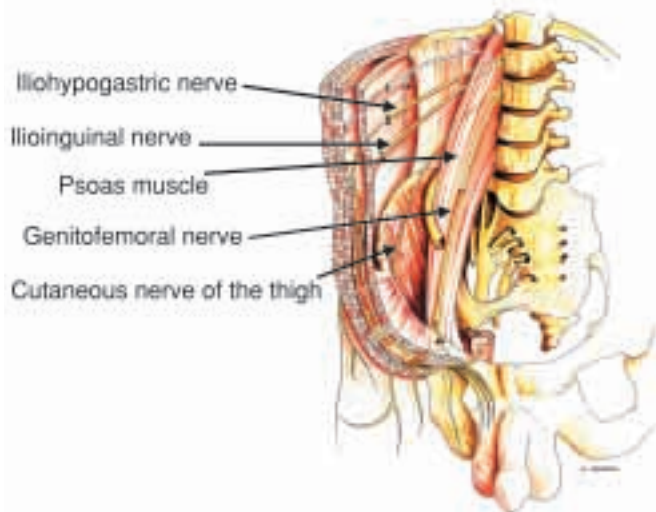


Figure 2: Ilioinguinal nerve block
B: Anatomical relationships: posterior and lateral wall of the abdomen

Anatomical considerations: The ilioinguinal and iliohypogastric nerves are terminal branches of the lumbar plexus, both deriving from L1 roots, which supply sensory innervation to the inguinal region, the spermatic cord and upper part of the scrotum and penis (Figure 2A). The two nerves emerge at the lateral border of the psoas muscle and run within the lateral (Figure 2B) then anterior wall of the abdomen. The iliohypogastric nerve crosses the transversus abdominis muscle and runs obliquely along the posterior aspect of the internal oblique muscle; at the level of the iliac crest it divides into a lateral branch supplying the buttock and a medial branch supplying the abdominal wall, above the pubis (Figure 2C).

The ilioinguinal nerve runs parallel to the iliohypogastric nerve but more caudally and in a distinct fascial plane; it crosses obliquely the quadratus lumborum and the iliacus muscle, then pierces the transversus abdominis (at the level of the iliac crest), enters the oblique muscles and finally reaches the lower border of the spermatic cord (or the round ligament of the uterus) within the inguinal canal (Figure 2C). It supplies sensory innervation to the upper part of the thigh, the spermatic cord, scrotum and penis in males or round ligament, labia major and mons pubis in females.

A third branch contributes sensory fibres to the inguinal canal: the genital branch of the genitofemoral nerve. This branch too has to be blocked to ensure pain-free surgery of the inguinal region and adequate postoperative pain relief.

Technique: Classically, the technique consisted of 3 injections of local anaesthetics: 1) two below the superficial and deep aponeuroses of the oblique muscle respectively, and 2) one at the level of the pubic spine (which could damage an undescended testis or a herniated intestinal loop). In fact, a simplified technique (12) can be used instead with a higher success rate. It consists of injecting the local anaesthetic closer to the inguinal canal, where both the iliohypogastric and ilioinguinal nerves run at the inner surface of the external aponeurosis of the external oblique muscle. At this level, the genitofemoral nerve gives off in the same fascial plane its genital branch which reaches the spermatic cord: thus, with a single injection, the three nerves supplying the inguinal region are simultaneously blocked.

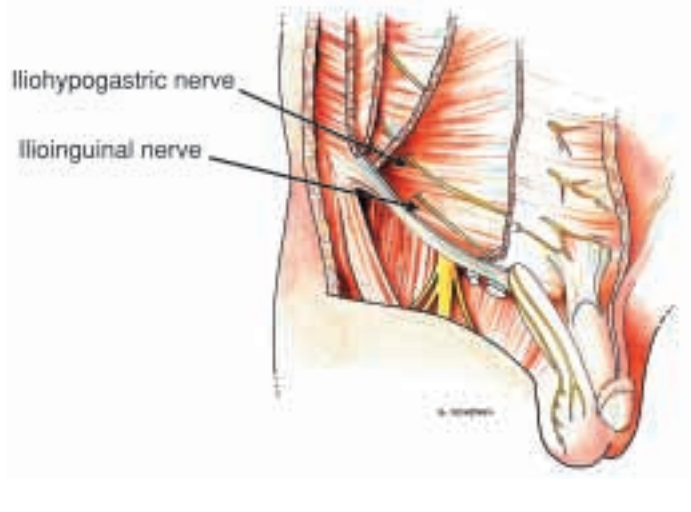


Figure 2: Ilioinguinal nerve block
C: Anatomical relationships: anterior wall of the abdomen

The block procedure is performed with the child placed in the dorsal recumbent position. The puncture site is located at the union of the lateral with the medial three quarters of the line uniting the umbilicus to the anterior superior iliac spine (located by palpation). A short-bevelled needle is inserted at a 45 to 60° angle to the skin pointing towards the midpoint of the inguinal ligament until the external aponeurosis of the external oblique muscle is pierced, usually with some difficulty and a clearly identifiable give (Figure 2D). Then, a single injection of 0.3 to 0.4 ml/kg of 0.25-0.5% bupivacaine (up to 10 ml) is made in a fan shape manner. The overall success rate of the technique is higher than 95% and the distribution of anaesthesia allows pain free surgery of the inguinal area.

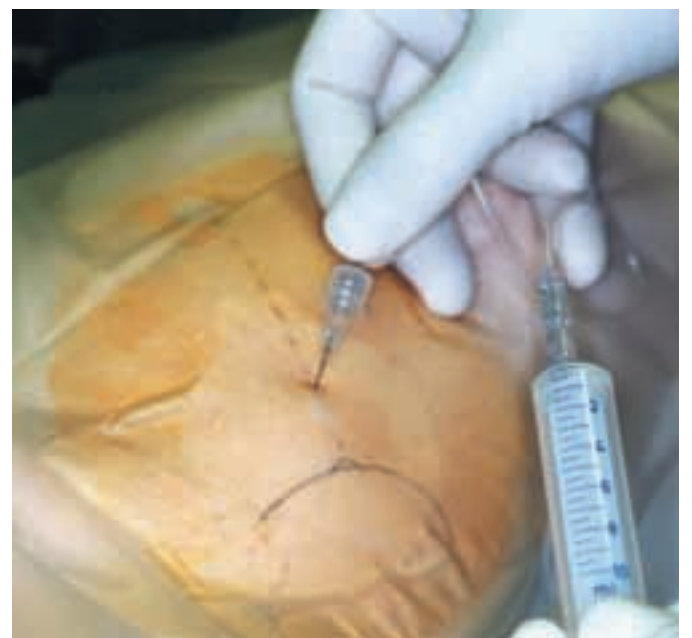

Figure 2: Ilioinguinal nerve block
D: Technique

Pudendal/Perineal Nerve Block

Indications, contraindications and complications: Before epidural anaesthesia has gained such a widespread popularity for pain relief during childbirth, blocking the pudendal nerve was mainly used in obstetrics. This nerve

which supplies division branches to the peri-anal region, the scrotum, and the penis, can be easily blocked near the ischial tuberosity, thus adequately complementing an ilioinguinal/hypogastric nerve block when a scrotal incision is necessary (surgery of undescended testis especially). Children undergoing surface surgery of the anal area would also benefit from this block. Occasionally, the technique can be used to provide analgesia in females during and after surgery of the labia minores, which are not very common procedures in paediatrics. The dorsal nerve of the penis is a terminal branch of the pudendal nerve: complete blockade of this nerve, which is difficult to achieve because of its so many division branches at the level of the ischial tuberosity, also provides analgesia to the skin covering the penis and Serour et al. (13) reported consistent improvement of their technique of penile dorsal nerve block when combined with a pudendal nerve block.

Indications, contraindications and complications: Before epidural anaesthesia has gained such a widespread popularity for pain relief during childbirth, blocking the pudendal nerve was mainly used in obstetrics. This nerve which supplies division branches to the peri-anal region, the scrotum, and the penis, can be easily blocked near the ischial tuberosity, thus adequately complementing an ilioinguinal/hypogastric nerve block when a scrotal incision is necessary (surgery of undescended testis especially). Children undergoing surface surgery of the anal area would also benefit from this block. Occasionally, the technique can be used to provide analgesia in females during and after surgery of the labia minores, which are not very common procedures in paediatrics. The dorsal nerve of the penis is a terminal branch of the pudendal nerve: complete blockade of this nerve, which is difficult to achieve because of its so many division branches at the level of the ischial tuberosity, also provides analgesia to the skin covering the penis and Serour et al. (13) reported consistent improvement of their technique of penile dorsal nerve block when combined with a pudendal nerve block.

Anatomical considerations: The perineal region receives its sensory innervation from several terminal branches of the pudendal nerve, including the perineal nerve which supplies the scrotum. The pudendal nerve emerges from the sacral plexus and reaches the ischiorectal fossa. At its emergence from the Alcock canal, it reaches the medial aspect of the ischial tuberosity and divides into several




Figure 3: Pudendal/perineal nerve block
A: Landmarks

terminal branches including the inferior hemorrhoidal nerve, the perineal nerve and the dorsal nerve of the penis (or clitoris).

Technique: The child is placed in the dorsal recumbent position, with his thighs abducted, knee flexed and the plantar aspects of his feet conjoined (as for bladder catheterisation in young girls). The main landmark is the ipsilateral ischial tuberosity which is located by palpation, lateral to and slightly above the anus. The puncture site corresponds to the skin projection of this tuberosity in the frontal plane (Figure 3A). A short bevel needle is inserted at a 60-80 degree angle to the skin from medially to laterally, pointing to the upper part of the medial aspect ischial tuberosity until a clearly identifiable "give" is felt as the pelvis fascia is traversed (Figure 3B). The local anaesthetic is then injected just below this fascia in order for the solution to spread along its inner surface and reach the division branches of the pudendal nerve. Due to the proximity of the pudendal artery which is a terminal artery, plain local anaesthetics only must be administered, mainly 0.5% bupivacaine at a dose of 0.1-0.2 ml/kg up to a maximum of 5 ml.

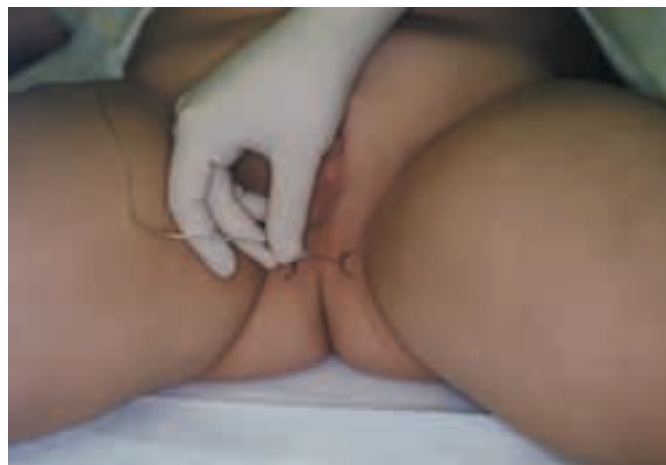

Figure 3: Pudendal/perineal nerve block
B: Technique

Block of the dorsal nerve of the penis via the subpubic space

Indications, contraindications and complications: Penile block via the subpubic space is the best technique to provide intra and postoperative analgesia for surface operations on the penis, i.e., foreskin (circumcision) and glans, which are very common surgical procedures in paediatric male patients. It is recommended for providing long-lasting pain relief after hypospadias repair: in this case, the block is usually performed at the end of the surgery whilst intraoperative analgesia, which requires a more extended distribution of anaesthesia, is usually provided by a caudal anaesthesia. Penile blocks via the subpubic space have no specific contraindications but, as the dorsal nerve runs close to a terminal artery (dorsal artery of the penis), only plain local anaesthetics must be injected.

Severe complications have been reported with certain techniques of penile block which are no longer used. Midline puncture techniques can injure the dorsal artery of the penis leading to a compressive haematoma, possi-

bly resulting in glans necrosis. Use of local anaesthetic containing adrenaline can lead to a spasm of the dorsal arteries with subsequent necrosis of the glans (14).

Anatomical considerations: The penis is mainly supplied by the dorsal nerves of the penis, one per side, which are terminal branches of the pudendal nerve. Soon after their emergence from the pudendal nerve, near the ischial tuberosity, the dorsal nerves pass under the pubic bone, cross the subpubic space sagittally from back to front, enter the suspensory ligament then the penis where they run along the inner surface of Buck's fascia accompanied by the ipsilateral dorsal artery and vein. During their course, they supply sensory innervation to the corpora cavernosa, the skin covering the penis and the foreskin, the glans and the frenulum, before they end in the glans penis. Apart from the dorsal nerves, the penis is also supplied by a few branches deriving from the genitofemoral, ilioinguinal and, occasionally, perineal nerves, which contribute to sensory innervation to its proximal part and, occasionally, its ventral aspect (15).

The dorsal nerves can be easily blocked by injecting a local anaesthetic into the subpubic space. This space is covered by the easily identifiable deep membranous layer of the superficial fascia of the abdomen, also termed Scarpa's fascia, which is in continuation with Buck's fascia (Figure 4A). The subpubic space is filled with loose areolar, fatty tissue and the local vascularity is low making inadvertent vascular punctures unusual. Medially, the suspensory ligament of penis tends to divide the subpubic into two compartments which, occasionally, can be completely separate, preventing spread of local anaesthetic from one side to the other.

Technique: The child is placed supine and the penis is pulled down to stretch Scarpa's fascia (16). The landmarks are the symphysis pubis and the lower border of the iliac branches of the pubic bone located by palpation. Two symmetrical puncture sites are identified just below the iliac branches, at a distance of 0.5-1cm from the midline (Figure 4B). A 30 mm-long needle with a 45-60° bevel (a caudal or neonatal lumbar tap needle is perfectly suitable) is inserted almost perpendicularly to the skin, with a slight inclination caudally and medially, until it pierces Scarpa's fascia (often, but not constantly depending on the stretching of the fascia, with a characteristic "give"), at a distance from skin ranging from 10 to 25 mm

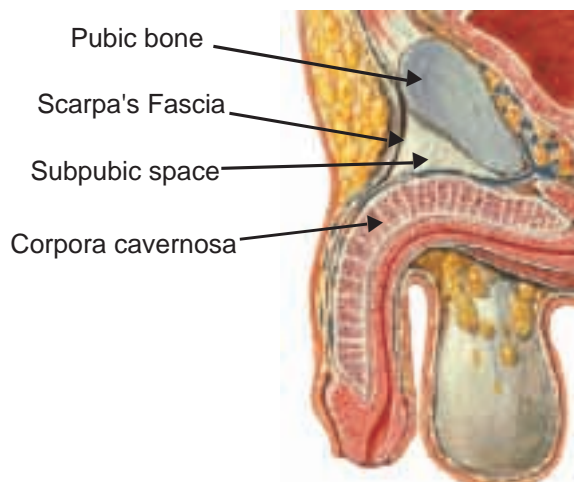


Figure 4: Penile block via the subpubic space
A: Anatomical relationships

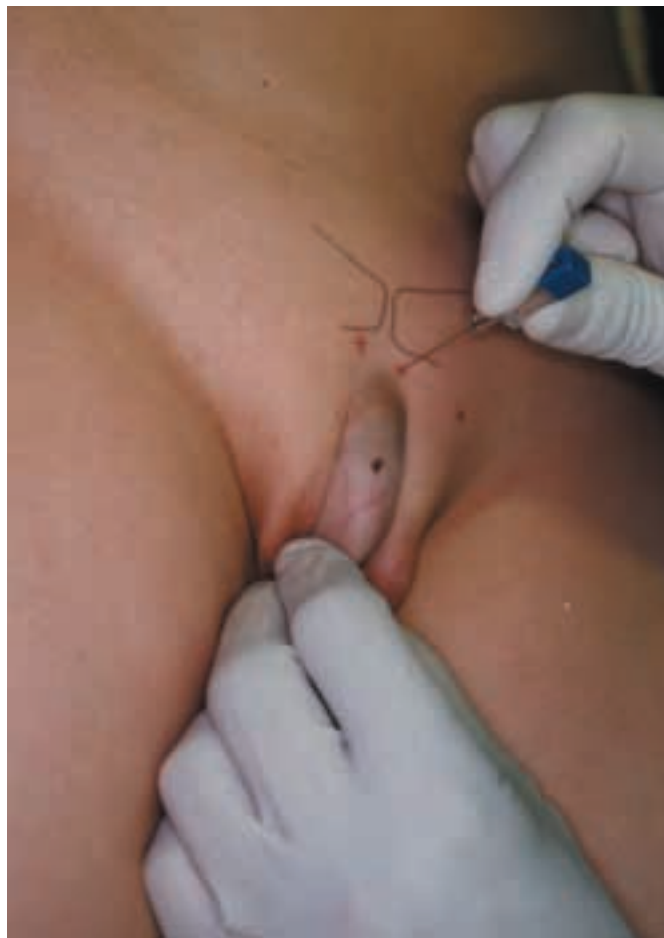


Figure 4: Penile block via the subpubic space
B: Landmarks and technique

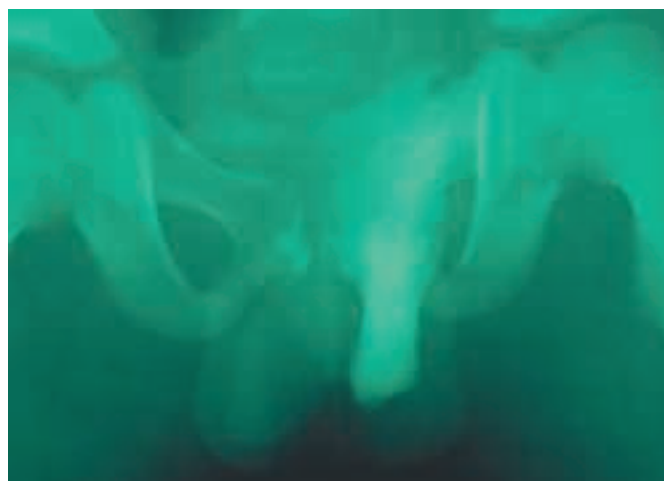

Figure 4: Penile block via the subpubic space
C: Unilateral spread of the solution

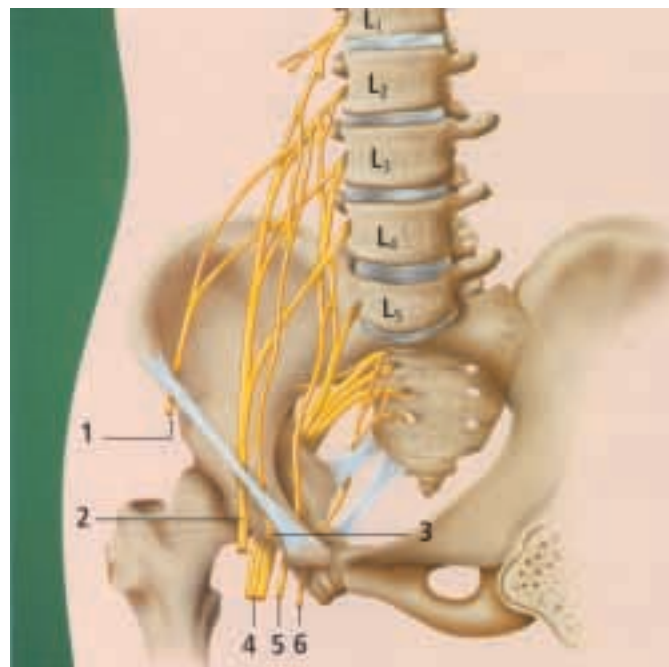
irrespective of the age and weight of the patient. When the needle is let free, it should not move: if Scarpa's fascia has not been pierced, it will push back the needle when no more pressure is exerted on it. The local anaesthetic is then injected according to the safety rules.

The same procedure is then repeated at the symmetrical puncture site to avoid unilateral blockade in the event the subpubic space is divided into two non-communicating compartments by the suspensory ligament of the penis (Figure 4C). The recommended local anaesthetic is 0.5% bupivacaine without adrenaline administered at a

dose of 0.1 ml/kg per side (up to a maximum of 5 ml per side). The duration of sensory blockade may be as long as 24 hours due to the entrapment of the local anaesthetic in the fatty and poorly vascularised tissue content of the subpubic space (17).

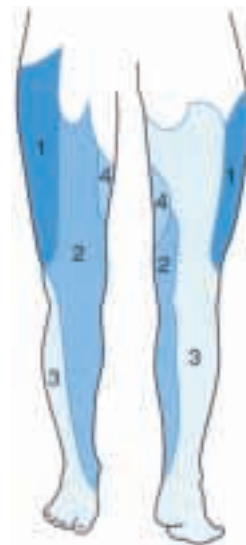Fascia Iliaca Compartment Block

Indications, contraindications and complications: The fascia iliaca compartment block aims at blocking the lumbar plexus nerves supplying the thigh by injecting local anaesthetics under inner surface of the fascia iliaca. The main indications of the technique (18) are for providing pain relief in children with a fractured femoral shafts. The block should be performed as early as possible to improve comfort and safety of the patient during transport, radiological examinations, wound dressings and orthopaedic procedures. It can be repeated if necessary and placement of a cannula or a catheter below the fascia iliaca allows repeated and continuous injection of local anaesthetic, thus providing long lasting pain relief. The technique is also recommended for elective surgery of the soft tissues of the thigh (especially outpatient surgery) and the femur; it may represent a safer alternative to epidural anaesthesia, especially since catheter placement would allow long-lasting pain relief (19, 20).



- 1 Lateral femoral cutaneous nerve
- 2 Femoral nerve
- 3 Genitofemoral nerve
- 4 Sciatic nerve
- 5 Obturator nerve
- 6 Pudendal nerve

Figure 5: Anatomy of the lumbar (and sacral) plexus (Figure 3 from Tutorial from the Ulm rehabilitation hospital, page 10)



- 1 Lateral femoral cutaneous nerve
- 2 Femoral nerve
- 3 Sciatic nerve
- 4 Obturator nerve

Figure 6: Sensory supply of the lower limb (Figure 5 from Tutorial from the Ulm rehabilitation hospital, page 11)

Anatomic considerations: Nerve supply to the lower limb is more complicated than that of the upper limb as it depends on two plexuses, lumbar and sacral. The lumbar plexus is formed by the union of L1 to L4 spinal roots (Figure 5). It supplies the ventral aspect of the limb (Figure 6). It lies within the substance of the psoas muscle, in a fascial compartment usually termed the "psoas compartment". All the nerves emerging from the lumbar plexus run a variable but constant part of their course along the inner aspect of the fascia covering the psoas

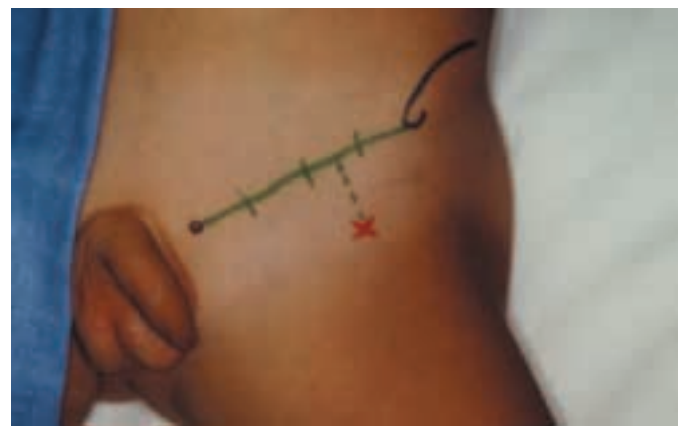

Figure 7: Fascia iliaca compartment block
A: Landmarks

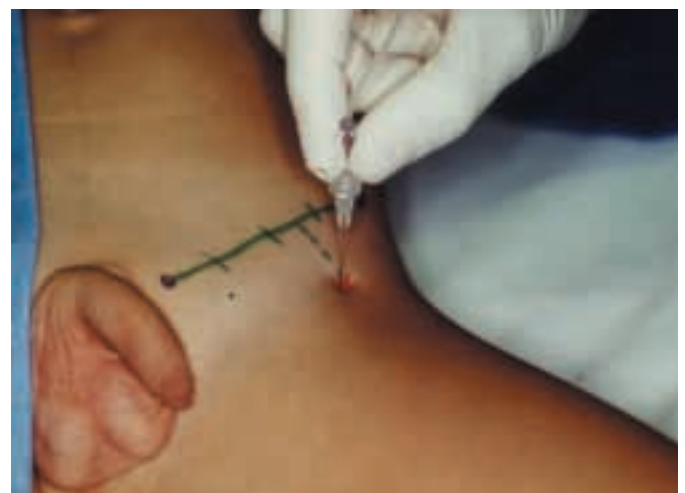


Figure 7: Fascia iliaca compartment block
B: Technique

(which also covers the iliacus muscle), i.e., the fascia iliaca: any sufficient volume of local anaesthetic will spread along the inner surface of this fascia and anaesthetise all the contacted lumbar plexus nerves.

Technique: The child is placed in the dorsal recumbent position, preferably (if acceptable) with the thigh slightly abducted and laterally rotated (but any position is suitable). The main landmark is the inguinal ligament extending from the anterior superior iliac spine to the pubic spine located by palpation. The site of puncture is identified 0.5-1 cm caudal to the union of the lateral with the medial two thirds of the skin projection of the inguinal ligament (Figure 7A), i.e., at significant distance from the femoral artery (and the femoral nerve). A short-bevel non-insulated needle, connected via an extension line to the syringe filled with the local anaesthetic, is then inserted vertically (Figure 7B) until it pierces the two underlying fascial planes with a clearly identifiable loss of resistance (often with an audible "click" noise): the first loss of resistance corresponds to the crossing of the fascia lata and the second one to that of the fascia iliaca.

The local anaesthetic is injected following the safety rules. Commonly used local anaesthetics are displayed in Table 1 and recommended volumes of injection in Table 2. Massaging the swollen area favours upward spread of the solution at the inner surface of the fascia iliaca, improving the chances of reaching distant lumbar plexus nerves such as the obturator nerve (which remains unblocked in 25% of cases approximately).

Depending on the mandatory duration of analgesia, lignocaine, mepivacaine, bupivacaine or ropivacaine can be administered at different concentrations (depending on the need for motor blockade). Due to the rather large surface along which the solution spreads, increased vascular absorption might occur; however, acceptable peak plasma concentrations were measured, following injection of 2 mg/kg of bupivacaine, either plain or with adrenaline (21), even though the higher concentrations were observed following administration of plain solutions.

Metacarpal (Transthecal) Block

Indications, contraindications and complications: The technique aims at infiltrating the flexor tendon sheath which surrounds the synovial sheath of the flexor tendon of each digit and within which run the four digital nerve supplying the relevant finger. The metacarpal/transthecal block procedure is recommended for any surgery on the relevant digit (either traumatic or elective). This technique is an alternative to digital nerve blocks with many advantages: it is a safer (no terminal artery in close proximity), simpler (a single injection is made) and less painful procedure (even though injection is not pain-free) in conscious patients. Caution should be taken in case of infection; if there is a possibility of bacterial contamination of the synovial sheath, the technique should be considered contra-indicated. This block is very simple and is virtually free of complication. Its only real drawback is that puncturing the flexor tendon sheath is unpleasant, even painful.

Anatomical considerations: The ventral aspect of each digit is centred by one flexor tendon wrapped in a synovial sheath the role of which is to allow movements of the tendon without friction. Outside the synovial sheaths there is a membranous sheath derived from the palmar aponeurosis extending from the head of each metacarpal bone to the distal phalanx delineating a closed longitudinal canal surrounding each flexor tendon and called the flexor tendon sheath (22,23). The four digital nerves which supply each digit run within this canal and outside the digital synovial sheath of the flexor tendons. A single injection of local anaesthetic within this flexor tendon sheath will reach the core of the digit and all four digital nerves by circumferential spreading.

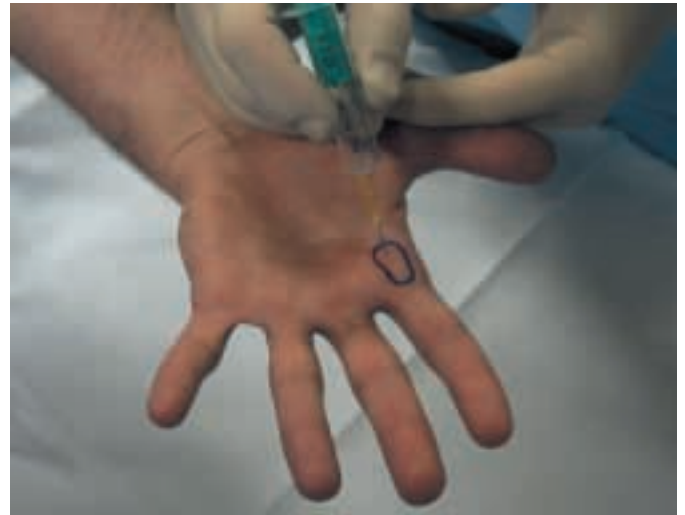

Figure 8: Metacarpal (Transthecal) Block Landmarks, Technique

Technique: The technique is performed with the hand supinated. The main landmark is the head of the relevant metacarpal bone located by palpation. Right in the centre of the skin projection of this metacarpal head, an intradermalic needle is inserted perpendicularly to the palmar aspect of the hand (Figure 8) until bone contact is made. The needle is then slightly withdrawn to avoid subperiosteal injection. At this time, any flexion of the distal phalanx of the relevant digit is transmitted to the needle. However, this confirmation is not necessary and the syringe filled with 2-3 ml of a plain solution of local anaesthetic (lignocaine or bupivacaine) can be connected directly to the needle (to avoid any inadvertent displacement of the needle). A volume of 1 to 3 ml of the local anaesthetic (depending on the patient's size) is slowly injected: the injection must be stopped when resistance is felt. Within 2 minutes all four digital nerves (2 ventral and 2 dorsal) are fully anaesthetised in more than 95% of patients (24, 25).

Plexus and conduction nerve block

Plexus and conduction nerve blocks require a good knowledge of anatomy, especially anatomical relationships to be achieved both successfully and safely. Most such nerves are mixed nerves which are localised precisely with the help of a nerve stimulator. Selection of block needles is critical: they must be short-bevelled, insulated, of appropriate length to reach the nerve path but not too long to avoid damage to deeper structures.

Brachial Plexus Nerve Blocks

Indications, contraindications and complications: The aim of the technique is to inject a local anaesthetic within the fascial envelope surrounding the plexus, either the interscalene (above the clavicle) or the axillary sheath (in the axilla). The brachial plexus and its terminal branches can be approached in many ways. Basically, there are two

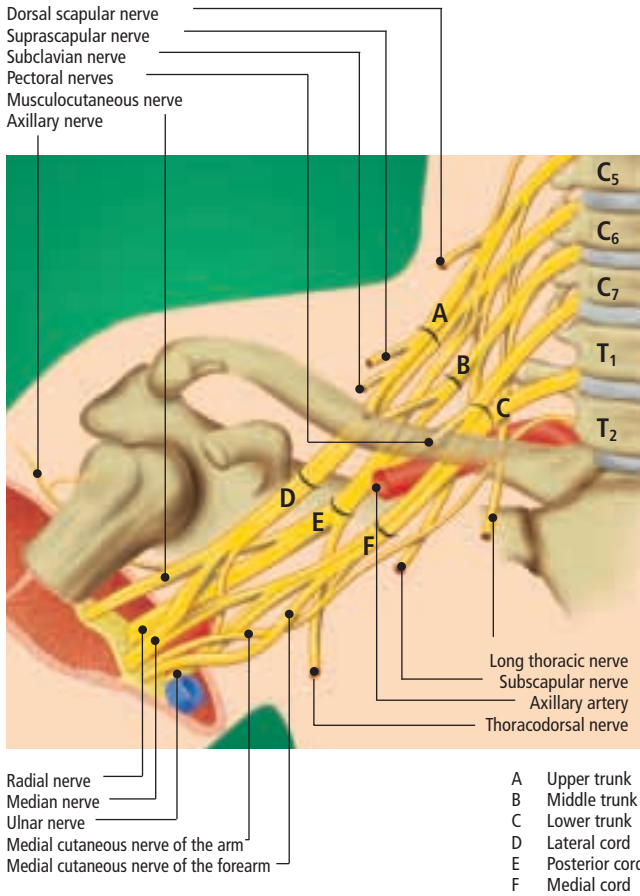


Figure 9: Anatomy of the brachial plexus (Figure 1 from Tutorial from the Ulm rehabilitation hospital, page 7)

mains types of approaches: **plexus** approaches, above the clavicle, and **plexus nerve** approaches below the clavicle, the morbidity of which differs significantly. Axillary blocks should be preferred whenever they are suitable, especially for elective and emergency surgery on the forearm and the hand. These blocks have few contraindications, mainly represented by lymphadenopathy (infectious or malignant) and their morbidity is very low.

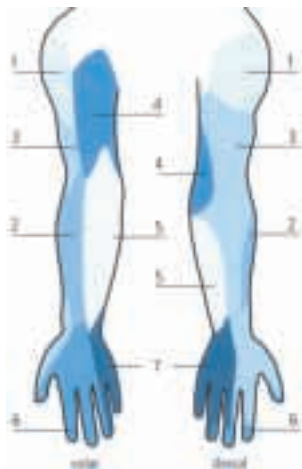

Figure 10: Sensory supply of the upper limb (Figure 2 from Tutorial from the Ulm rehabilitation hospital, page 9)




Figure 11: Opacification of the interscalene space during a parascalene block procedure. Note the lack of spread of contrast material below the scapula.

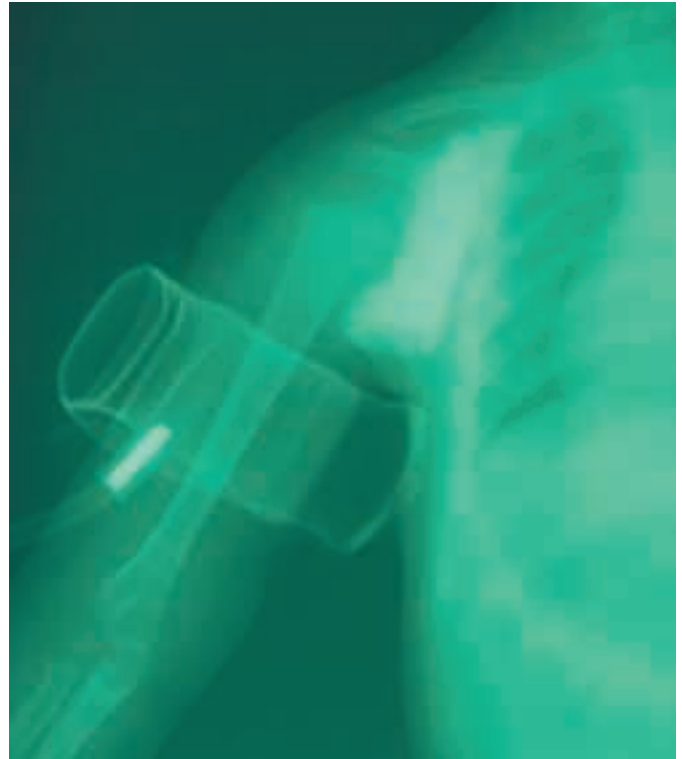


Figure 12: Opacification of the axillary sheath: note the lack of spread of contrast material above the scapula. Even in presence of an inflated tourniquet the contrast material does not spread to the interscalene space.

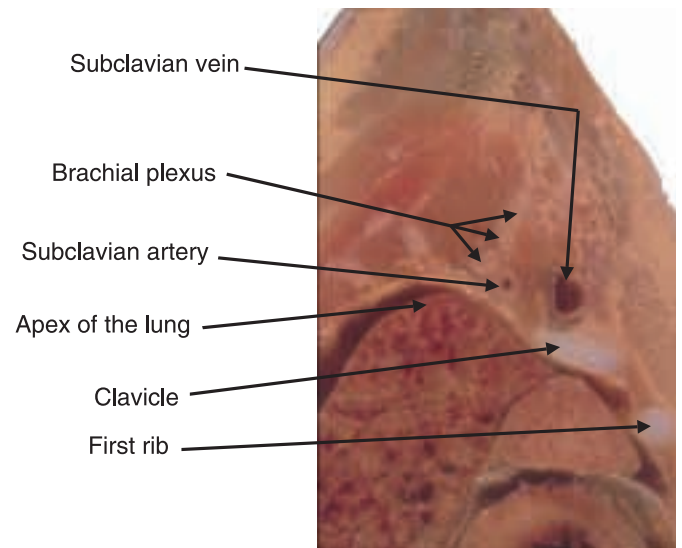


Figure 13: Parasagittal cross-section of the body at the midpoint of the clavicle in a neonate. Note that the apex of the lung is located above the first rib and clavicle.

Supraclavicular approaches are considered when the operative field involves the arm and/or shoulder, or when the limb cannot be positioned for performing an axillary block either due to the pain or the lesion (in emergency conditions). Classical contraindications to supraclavicular blocks procedures include bilateral blockade and marked respiratory insufficiency (acute or chronic) due to the potential danger of pneumothorax and (bilateral) phrenic nerve palsy. The parascapular approach (26,27,28), however, does not have the same limitations as the technique does not threaten any vital organs, especially the apical pleura.

Anatomic considerations: The brachial plexus is formed by the union of the ventral rami of the 5th cervical to the 1st thoracic spinal nerves (Figure 9). It supplies sensory, motor and sympathetic innervation to the upper extremity (Figure 10). It lies in the interscalene space, a fascial compartment derived from the deep cervical fascia and limited by the anterior and middle scalene muscles. The interscalene space ends caudally at the level of the coracoid process of the scapula and does not communicate with the axillary region (Figure 11); no local anaesthetic injected in the interscalene space can spread to the axilla and no solution introduced in the axillary sheath can reach the interscalene even if a tourniquet is used (Figure 12). Supraclavicular and axillary blocks are not equivalent.

The interscalene space is very close to the great vessels of the neck and the spine medially. Caudally, it is close to the subclavian vessels and the apical pleura. In infants, the upper part of the lung lies above the superior foramen of the thorax, i.e. in the neck (Figure 13): the subclavian vessels do not project above but below the apical part of the lung. Thus, any subclavian approach to the brachial plexus directly threaten the underlying lung and will sooner or later results in pneumothorax. No needle should be introduced below the horizontal plane lying 1 cm above the clavicle.

Below the clavicle, the plexus consists of three trunks (lateral, medial and posterior) which redistribute their fibres in three cords surrounding the axillary artery. From

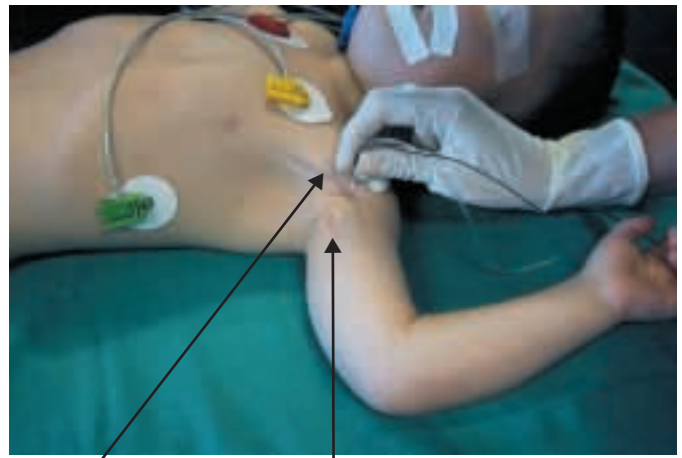
Musculocutaneous nerve



Axillary artery

Figure 14: Dissection of the axillary region in a neonate.

these cords emerge the terminal nerves of the plexus: the ulnar nerve medially, the median nerve above or slightly lateral to the artery, and the radial nerve posterior to the artery. The musculocutaneous nerve emerges from the lateral cord at the upper border of the pectoralis minor



Pectoralis major Coracobrachialis muscle

Figure 15: Trans-coracobrachialis axillary approach to the brachial plexus.

muscle and penetrates the coracobrachialis muscle (Figure 14). The level at which the musculocutaneous nerve leaves the axillary sheath is variable: in half the patients, it emerges above the skin projection of the coracoid process of the scapula and then will not be contacted by a local anaesthetic injected via the axilla: the lateral aspect of the forearm will not be anaesthetised.

Axillary approaches to the brachial plexus: The same techniques as used in adult are suitable for children except for the transaxillary artery approach. Their main limitation is the inconstant blockade of the musculocutaneous nerve. As this nerve runs within the coracobrachialis muscle, which is easily identifiable by palpation, a **trans-coracobrachialis approach** will almost constantly provide complete blockade of the median, ulnar, radial and musculocutaneous nerves. The relevant arm is abducted by 90° as in classical approaches. The landmarks are the lower border of the pectoralis major muscle and the lateral border of the coracobrachialis muscle. The site of puncture lies slightly medial to the crossing of these two border (in order to insert the block needle through the substance of the coracobrachialis muscle) (Figure 15). The needle is inserted vertically, pointing to the lower border of the humerus, just above the axillary artery which is firmly held by finger compression, until a "click" is felt and twitches are elicited. Whatever the technique used and unlike adults, location of several nerves and administration of fractionated doses of local anaesthetic in children bring no benefit to the quality of sensory and motor block (29). However, selective block of the musculocutaneous nerve (which is systematically achieved with trans-coracobrachialis approach) is recommended when a surgical procedure takes place in this territory. Commonly used local anaesthetics are displayed in Table 1 and recommended volumes of injection in Table 2.

The development of catheter placement techniques is revolutionising postoperative pain management. Even though it is still under evaluation, this technique allows safe and long-lasting pain management of patients (30). The technique allows both intermittent bolus administration, continuous infusion and self administered bolus injection of diluted solutions of local anaesthetics. Commonly administered bolus doses of local anaesthetics range from 0.2 to 0.4 ml/kg (up to 10 ml) of 0.5-1% lignocaine or mepivacaine every 6 (or, at the very maximum, 4) hours. Continuous infusion of 0.1-0.125% plain bupivacaine (or 0.2% ropivacaine) at a rate of 0.5 ml per hour and per

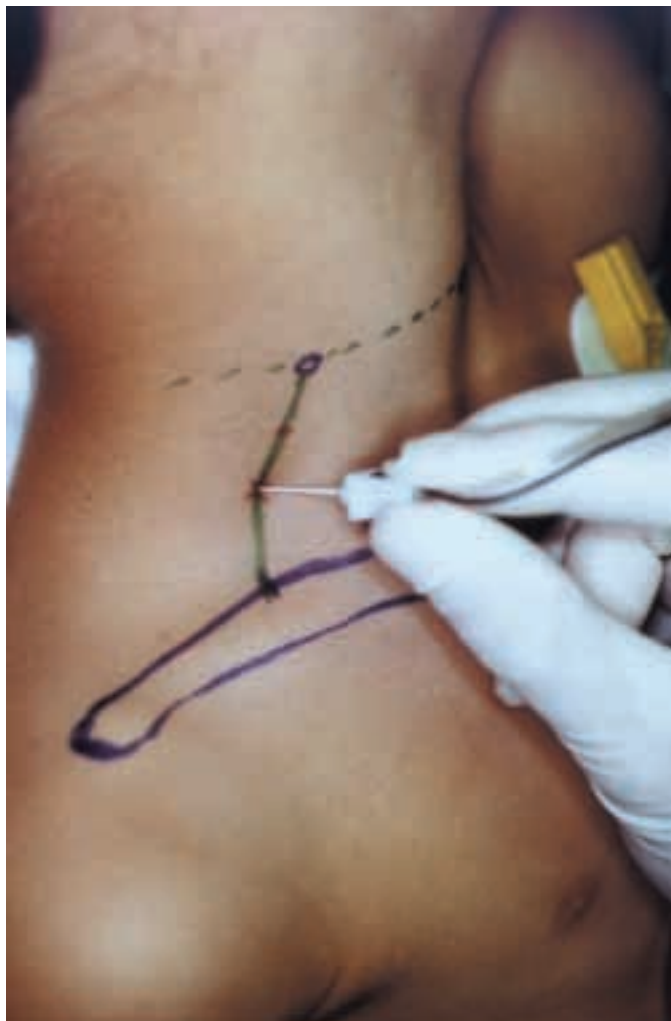


Figure 16: Parascalene approach to the brachial plexus

year of age is very effective and can be safely maintained for days when necessary. Hazards of toxicity are virtually nil and the main adverse effects are represented by accidental removal, especially because the pain-free children do not pay enough attention to their catheter.

Supraclavicular approaches to the brachial plexus: As for axillary blocks, virtually all the techniques used in adults have been, and occasionally still are (31) used in children, but only the interscalene and the parascalene approaches are still commonly performed, the latter being the safest approach (26,27,28).

The parascalene block is performed on a child placed in the supine position, arms extended along the body and the head turned to opposite side. A rolled sheet is slipped under the shoulders in order to extend the neck, stretch and make the components of the brachial plexus superficial. The landmarks are: 1) the upper border of the clavicle, 2) the skin projection of C6 transverse process (lying on the circular line passing over the cricoid cartilage) at the posterior border of the sternocleidomastoid muscle. The site of puncture is located at the union of the upper two thirds with lower third of the line joining C6 skin projection to the midpoint of the upper border clavicle. The needle is inserted perpendicularly to the horizontal plane until twitches are elicited in the upper limb (Figure 16). The distance from skin to one of the roots or trunks of the brachial plexus is correlated with the patient's age and weight, varying from 7 mm (\pm 3 mm) in neonates to 25 mm (\pm 6 mm) in adolescents weighing more than 80 kg. Commonly used local anaesthetics are displayed in Table

1 and recommended volumes of injection in Table 2.

The overall success rate of the technique is high (26,32,33,34). The upper branches of the brachial plexus are anaesthetised earlier whereas blockade of the distal branches (median, radial and ulnar nerves) are often delayed and, sometimes (rarely), incomplete. Morbidity of the parascalene technique is extremely low and even Horner's syndrome is unlikely (less than 5% of procedures); only a very faulty technique ("... as suggested by the marked resistance to injection, by the agonizing pain experienced by the patient...") can result in adverse effects (54).

A catheter can be introduced within the interscalene space to provide long-lasting pain relief, either by intermittent, continuous and/or patient-controlled delivery of bolus doses of local anaesthetic (35,36). Patient-controlled delivery of local anaesthetic provides better pain relief, less adverse effects (nausea and vomiting especially) and better patient satisfaction than patient-controlled intravenous analgesia with opioids (37). Catheter fixation is easier at neck level than in the axilla and the danger of accidental removal is minimised.

Lumbar Plexus Nerve Blocks

Indications, contraindications and complications: The lumbar plexus can be approached percutaneously within the psoas compartment: this may represent a good, and safer, alternative to epidural anaesthesia for major operation of the proximal part of the lower limb, the more so as placement of a catheter is easy and would allow long-lasting pain relief (38,39). Most usually, lumbar plexus nerves, not the plexus itself, are approached for analgesic purposes. The femoral nerve is easily blocked in the thigh to provide analgesia in the trauma patient with a fractured shaft of the femur and in the elective patient undergoing surgery of the thigh and knee; in many indications however, a fascia iliaca compartment block (see above) is usually preferred. The obturator nerve block has very limited indications in children and the technique is neither easy nor safe. The saphenous nerve block is an excellent complementary block of a sciatic nerve block for providing complete analgesia of the leg and foot with reasonable amounts of local anaesthetics: this block is very effective, easy to perform and virtually free of complications.

Anatomical considerations: As previously mentioned (see fascia iliaca compartment block), the lumbar plexus is formed by the union of L1 to L4 spinal nerves (Figure 5) and supplies the anterior aspect of the limb (Figure 6). It

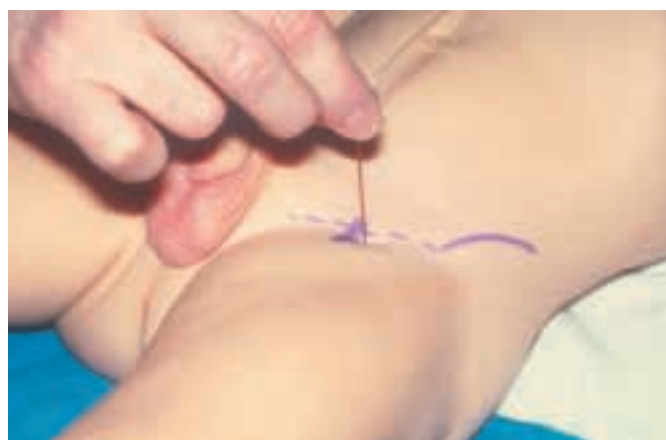

Figure 17: Specific femoral nerve block

is located in a fascial compartment within the substance of the psoas muscle termed the "psoas compartment" (40) where it can be directly approached from posteriorly. Its main terminal branches are the femoral, the lateral cutaneous and the obturator nerves. Only the femoral nerve is commonly blocked in children. Its main division branch is the saphenous nerve which provide sensory innervation to the medial aspect of the leg and the foot. This purely sensory nerve is not eligible for nerve stimulation. However, it runs in the thigh in the same fascial canal as the motor nerve to the vastus medialis muscle which can be located electrical stimulation: thus the canal enclosing the two nerves can easily be located and injection of a small amount of a local anaesthetic will result in complete blockade of the two nerves.

Specific femoral nerve block: Specific femoral nerve block is the easiest conduction block technique. The landmarks are the inguinal ligament, extending from the pubic spine to the anterior superior iliac spine, and the femoral artery (all landmarks located by palpation). The puncture site lies 0.5-1 cm both distal to the inguinal ligament and lateral to the femoral artery. The block needle is inserted at right angles to the thigh until paresthesia or twitches are elicited in the thigh (Figure 17). High quality of blockade is obtained with the injection of 0.5 to 0.75 ml/kg of a local anaesthetic (as for parascalene supraclavicular blocks). A catheter can be left in place for intermittent or continuous injections (same regimen as for axillary block), thus allowing long lasting postoperative pain relief (including pain-free mobilisation of joints).

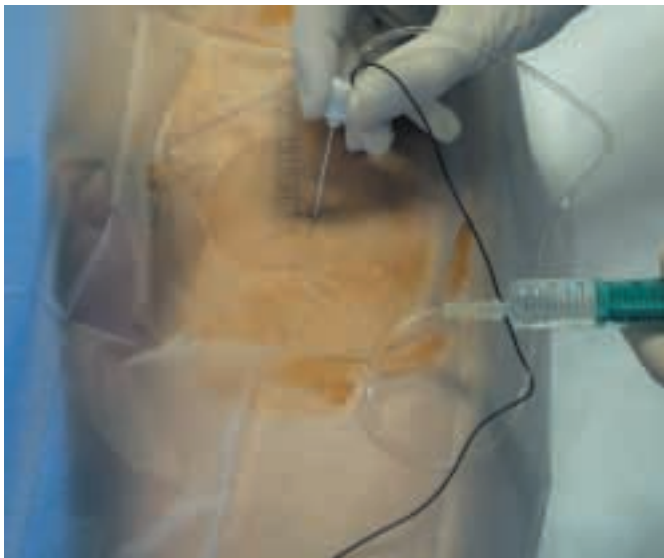


Figure 18: Saphenous/Vastus medialis nerve block

Saphenous/Vastus medialis nerve block: As mentioned above, this sensory nerve runs just lateral to the motor branch supplying the vastus medialis muscle, which can be easily located by nerve stimulation 0.5 cm lateral to the femoral artery and 3 to 6 cm (depending on patient's age and size) below the inguinal ligament. An insulated needle is inserted vertically until twitches are elicited in the vastus medialis (41) (Figure 18); then 0.1 to 0.2 ml/kg of local anaesthetic is injected and complete saphenous nerve block is obtained within 5 minutes. The very small amounts of local anaesthetic necessary to achieve complete blockade makes this block the ideal complement of a sciatic nerve block to ensure complete analgesia of the lower limb below the knee.

Sciatic Nerve Blocks

Indications, contraindications and complications: Sciatic nerve blocks are recommended for surgical operations below the knee, especially the foot in young children. However, the medial part of the leg down to the medial malleolus and, occasionally, the great toe, are not supplied by the sciatic nerve but by the saphenous nerve, the simultaneous block of which is mandatory to provide complete analgesia of the leg, ankle and foot. Sciatic nerve blocks have no specific contraindications. Whether irreversible damage to the sciatic nerve following intragluteal injections has been reported in the first quarter of the 20th century, both experimental data and clinical experience with the use of local anaesthetics have confirmed the safety of the procedure.

Anatomical considerations: The sciatic nerve is the main nerve emerging from the sacral plexus (Figure 5) which supplies the dorsal part of the lower extremity (Figure 6). It is the largest mixed nerve of the body and is, in fact, formed by two distinct nerves, the common peroneal nerve and the tibial nerve, in the same perineural sheath. Occasionally, these two nerves run separately and have to be blocked separately. The sciatic nerve leaves the pelvis through the greater sciatic foramen and passes between the greater trochanter of the femur and the ischial tuberosity. It then runs parallel to the lower border of the femur, on the adductor magnus, in the direction of the popliteal fossa where its two constitutive nerves separate. The common peroneal nerve supplies the lateral aspect of the leg and the dorsum of the foot. The tibial nerve supplies the dorsal aspect of the leg and the plantar surface of the foot.

Proximal lateral approach to the sciatic nerve: The sciatic nerve can be approached proximally via different insertion routes but the proximal lateral approach is the safest and easiest technique (42). The patient is placed in the dorsal recumbent position, the relevant limb slightly rotated towards medially if possible. The main landmark is the greater trochanter of the femur located by palpation. The insulated block needle of appropriate length (from 50 to 150 mm depending on the age and size of the child) is inserted parallel to the horizontal plane 1 to 2 cm below the lateral skin projection of the trochanter, pointing to the lower border of the femur until twitches are elicited in the foot (Figure 19). Commonly used local anaes-

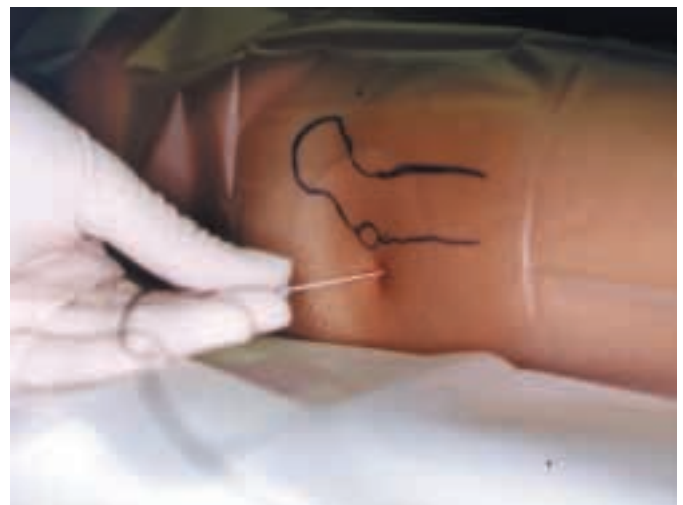

Figure 19: Proximal sciatic nerve block: lateral approach

thetics are displayed in Table 1 and recommended volumes of injection in Table 2. Proximal sciatic nerve blocks, including the lateral approach, result in long-lasting blockade (significantly longer than following any other nerve block with the same local anaesthetic). Whether this approach allows placement of catheter, it is not as easy and dependable as it is in the popliteal fossa and inadvertent removal occurs rather often.

Sciatic block in the popliteal fossa: The sciatic nerve can be approached in the popliteal fossa with smaller doses of local anaesthetics than following a proximal approach. In this fossa, the sciatic nerve and its branches lie below the popliteal membrane which has important clinical implications in regard to the spread of the local anaesthetic (43). A simplified single-shot technique was recently reported for use in children placed in the lateral decubitus position with the affected extremity lying uppermost (44). The landmarks are the limits of the popliteal fossa: 1) the tendon of the biceps femoris muscle laterally; 2) the tendon of the semi-tendinosus muscle medially; and 3) the horizontal skin crease of the knee joint. The landmarks are made more visible with the legs flexed at 30°. The site of puncture lies slightly lateral to bisecting line of the upper angle formed by the convergence of the two tendons, at the level of the union of the lower third with the upper two thirds (Figure 20A). An insulated needle is inserted cephalad at a 45° angle to the skin in direction to the femur until twitches are elicited in the sciatic territory.

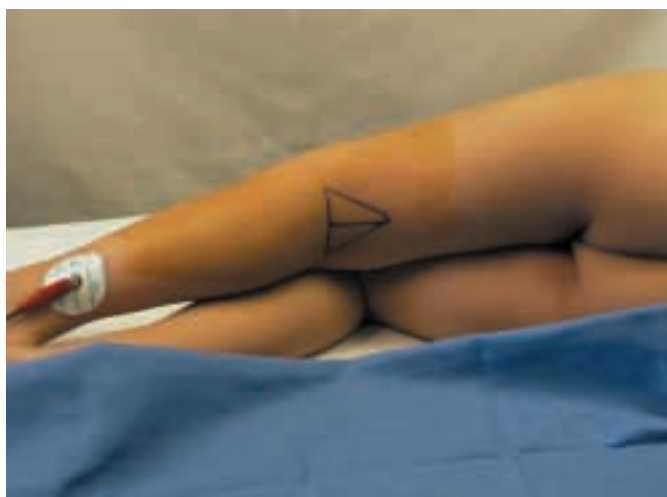

Figure 20: Sciatic nerve block in the popliteal fossa
A: Landmarks and insertion route

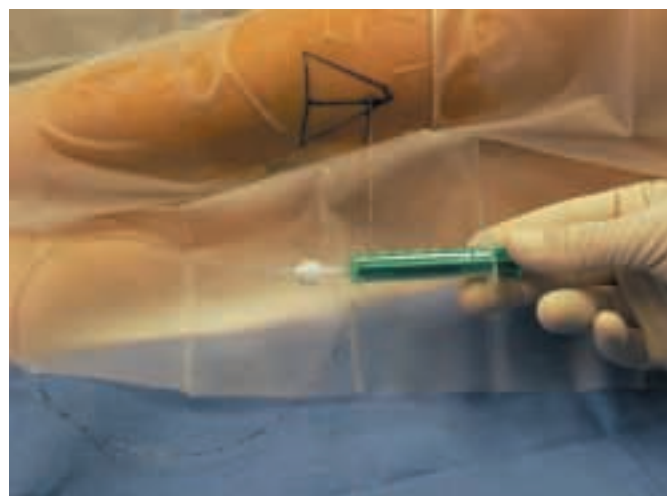


Figure 20: Sciatic nerve block in the popliteal fossa
B: Continuous technique

With an appropriate device, a catheter can be inserted along the sciatic nerve path which allows long lasting infusion of local anaesthetics (Figure 20B): this technique, still under development, is particularly appropriate to provide adequate and long-lasting postoperative pain relief after many operations on the foot, especially club foot surgery, in combination with a saphenous nerve block.

Conclusion

Peripheral blocks are being increasingly considered for use in children due to their many advantages. They provide limited distribution of anaesthesia, require smaller amounts of local anaesthetics than most central block procedures and are very safe with virtually no general or systemic effects. This interest is still enhanced by the considerable improvements in the design of devices made by the manufacturers which make the performance of such blocks not only possible but safe whatever the age of the patient, including the neonatal period. New perspectives, still under evaluation, are offered by the development of catheter techniques which allow long-lasting and well adapted analgesia either by repeat bolus injection just prior to short-lasting but repeated painful procedures (joint mobilisation), or continuous infusion (long-lasting pain) or both continuous infusion and self-administered additional bolus doses (allowing fine tuning of the level of analgesia under the control of the patient). Since there are no more theoretical reasons not to use peripheral blockades there seem to be practical limits because these techniques are basically not taught and anaesthesiologists are therefore not aware of it. Continuous education programs have to compensate for this incomplete training and the best way to achieve this goal is by establishing a progressive plan beginning with the easiest and most useful techniques, then progressively moving towards more complicated procedures. In this regard, infiltration techniques and compartment blocks are the simplest techniques, not requiring particular skills or sophisticated devices, the indications of which are numerous in daily paediatric anaesthetic practice. Once significant experience, and confidence, have been acquired with these procedures, the time has come to move forward to peripheral conduction nerve blocks. Whether these techniques look more complicated as they require the use of insulated needles of appropriate length connected to a nerve stimulator correctly adjusted, they do not need particular skills (less than those necessary for performing a tracheal intubation) but just some precise knowledge of local anatomy: the important point is the correct location of the puncture site. If this is achieved, the nerve stimulator will allow the anaesthetist to locate the nerve without error; if the needle is not put in the right place, whatever the skills of the practitioner, it will not be possible to find a nerve where it does not run.

References

1. Giaufre E, Dalens B, Gombert A. Epidemiology and Morbidity of Regional Anesthesia in Children - A One-Year Prospective Survey of the French-Language Society of Pediatric Anesthesiologists (ADARPEF). *Anesthesia and Analgesia* 1996; 83: 904-912.
2. Ferguson S, Thomas V, Lewis I. The rectus sheath block in paediatric anesthesia: new indications for an old technique? *Paediatr Anesth* 1996; 6: 463-61996.
3. Courrèges P, Poddevin F, Lecoutre D. Para-umbilical block: a new concept for regional anesthesia in children. *Paediatr Anesth* 1997; 7: 211-4.
4. Markham SJ, Tomlinson J, Hain WR. Ilioinguinal nerve block in children - A comparison with caudal block for intra and postoperative analgesia. *Anaesthesia* 1986; 41: 1098-103.
5. Johr M, Sossai R. Colonic puncture during ilioinguinal nerve block in a child. *Anesth Analg* 1999; 88: 1051-2.
6. Rosario DJ, Jacob S, Luntley J, Skinner PP, Raftery AT. Mechanism of femoral nerve palsy complicating percutaneous ilioinguinal field block. *Br J Anaesth* 1997; 78: 314-6.
7. Rosario DJ, Skinner PP, Raftery AT. Transient femoral nerve palsy complicating preoperative ilioinguinal nerve blockade for inguinal herniorrhaphy. *Br J Surg* 1994; 81: 897.
8. Derrick JL, Aun CS. Transient femoral nerve palsy after ilioinguinal block. *Anesth Intensive Care* 24: 1996; 115.
9. Stow PJ, Scott A, Phillips A, White JB. Plasma bupivacaine concentrations during caudal analgesia and ilioinguinal-iliohypogastric nerve block in children. *Anaesthesia* 1988; 43: 650-3.
10. Smith T, Moratin P, Wulf H. Smaller children have greater bupivacaine plasma concentrations after ilioinguinal block. *Br J Anesth* 1996; 76: 452-5.
11. Wulf H, Worthmann F, Behnke H, Böhle AS. Pharmacokinetics and pharmacodynamics of ropivacaine 2 mg/mL, 5 mg/mL, or 7.5 mg/mL after ilioinguinal blockade for inguinal hernia repair in adults. *Anesth Analg* 1999; 89: 1471-4.
12. Dalens B. Bloc ilioinguinal et iliohypogastrique chez l'enfant. In: Dartayet B. (ed), MAPAR. Paris 1997; p. 235-44.
13. Serour F, Mori J, Barr J. Optimal regional anesthesia for circumcision. *Anesth Analg* 1994; 79: 129-31.
14. Sara CA, Lowry CJ. A complication of circumcision and dorsal nerve block of the penis. *Anaesth Intens Care* 1984; 13: 79-85.
15. Jezior JR, Schwartz BF. Innervation of the human glans penis. *J Urol* 1999; 161: 97-102.
16. Dalens B, Vanneville G, Dechelotte P. Penile block via the subpubic space in 100 children. *Anesth Analg* 1989; 69: 41-5.
17. Wellington N, Rieder MJ. Penile block via subpubic space for children who underwent superficial operation of the penis. *Urol Int* 1994; 53: 147-149.
18. Dalens B, Vanneville G, Tanguy A. Comparison of the fascia iliaca compartment block with the 3-in-1 block in children. *Anesth Analg* 1989; 69: 705-13.
19. Longo SR, Williams DP. Bilateral fascia iliaca catheters for postoperative pain control after bilateral total knee arthroplasty: a case report and description of a catheter technique. *Reg Anesth* 1997; 22: 372-7.
20. Continuous fascia ilaca compartment block in children: a prospective evaluation of plasma bupivacaine concentrations, pain scores, and side effects. Paut O, Sallabery M, Schreiber-Deturmeny E, Rémond C, Bruguerolle B, Camboulives J. *Anesth Analg* 2001; 92: 1159-63.
21. Doyle E, Morton NS, McNicol LR. Plasma bupivacaine levels after fascia iliaca compartment block with and without adrenaline. *Paediatr Anesth* 1997; 7: 121-4.
22. Chiu DT. Transthecal digital block: flexor tendon sheath used for anesthetic infusion. *J Hand Surg [Am]* 1990; 15: 471-7.
23. Sarhadi NS, Shaw-Dunn J. Transthecal digital nerve block. An anatomical appraisal. *J Hand Surg [Br]* 1998; 23: 490-3.
24. Hill RG Jr, Patterson JW, Parker JC, Bauer J, Wright E, Heller MB. Comparison of transthecal digital block and traditional digital block for anesthesia of the finger. *Ann Emerg Med* 1995; 25: 604-7.
25. Low CK, Wong HP, Low YP. Comparison between single injection transthecal and subcutaneous digital blocks. *J Hand Surg [Br]* 1997; 22: 582-4.
26. Dalens B, Vanneville G, Tanguy A. A new parascalene approach to the brachial plexus in children: comparison with the supraclavicular approach. *Anesth Analg* 1987; 66: 1264-1271.
27. McNeely JK, Hoffman GM, Eckert JE. Postoperative pain relief in children from the parascalene injection technique. *Reg Anesth* 1991; 16: 20-22.
28. Vongvises P, Beokhaimook N. Computed tomographic study of parascalene block. *Anesth Analg* 1997; 84: 379-382.
29. Carre P, Joly A, Cluzel Field B, Wodey E, Lucas MM, Ecoffey C. Axillary block in children: single or multiple injection? *Paed Anaesth* 2000; 10: 35-9.
30. Scott DA, Schweitzer SA, Selander DE. Continuous axillary brachial plexus block for postoperative pain relief. Intermittent bolus versus continuous infusion. *Reg Anesth* 1997; 22: 357-62.
31. Pande R, Pande M, Bhadani U, Pandey CK, Bhattacharya A. Supraclavicular brachial plexus block as a sole anaesthetic technique in children: an analysis of 200 cases. *Anaesthesia* 2000; 55: 798-802.
32. McNeely JK, Hoffman GM, Eckert JE. Postoperative pain relief in children from the parascalene injection technique. *Reg Anesth* 16: 20, 1991.
33. Vongvises P, Beokhaimook N. Computed tomographic study of parascalene block. *Anesth Analg* 84: 379, 1997.
34. Baraka A, Hanna M, Hammoud R. Unconsciousness and apnea complicating parascalene brachial plexus block: possible subarachnoid block. *Anesthesiology* 77: 1046, 1992.
35. Klein SM, Grant SA, Greengrass RA, Nielsen KC, Speer KP, White W, Warner DS, Steele SM. Interscalene brachial plexus block with a continuous catheter insertion system and a disposable infusion pump. *Anesth Analg* 2000; 91: 1473-8.
36. Borgeat A, Kalberer F, Jacob H, Ruetsch YA, Gerber C. Patient-controlled interscalene analgesia with ropivacaine 0.2% versus bupivacaine 0.15% after major open shoulder surgery: the effects on hand motor function. *Anesth Analg* 2001; 92: 218-23.
37. Borgeat A, Tewes E, Biasca N, Gerber C. Patient-controlled interscalene analgesia with ropivacaine after major shoulder surgery: PCIA vs PCA. *Br J Anaesth* 1998; 81: 603-5.
38. Johnson CM. Continuous femoral nerve blockade for analgesia in children with femoral fractures. *Anesth Intensive Care* 1994; 22: 281-283.
39. Tobias JD. Continuous femoral nerve block to provide analgesia following femur fracture in a paediatric ICU population. *Anesth Intensive Care* 1994; 22: 616-618.
40. Chayen D, Nathan H, Chayen M. The psoas compartment block. *Anesthesiology* 45: 95, 1976.
41. Bouaziz H, Benhamou D, Narchi P. A new approach for saphenous nerve block. *Reg Anesth* 1996; 21: 490.
42. Dalens B, Tanguy A, Vanneville G. Sciatic nerve blocks in children: comparison of the posterior, anterior and lateral approaches in 180 pediatric patients. *Anesth Analg*, 1990; 70: 131-137.
43. Vloka JD, Hadzic A, Lesser JB, Kitain E, Geatz H, April EW, Thys DM. A common epineural sheath for the nerves in the popliteal fossa and its possible implications for sciatic nerve block. *Anesth Analg* 1997; 84: 387-90.
44. Konrad C, Jöhr M. Blockade of the sciatic nerve in the popliteal fossa: a system for standardization in children. *Anesth Analg* 1998; 87: 1256-1258.

Table 1: Commonly used local anaesthetics and doses (according to patient's weight).

LOCAL ANESTHETIC	Usual concentration (%)	Usual doses (mg/kg)	Maximum^a dose (plain) (mg/kg)	Maximum^a dose with epinephrine (mg/kg)	Latency (min)	Duration of effects (h)
Lidocaine	0.5-2	5	7.5	10	5-15	0.75-2
Mepivacaine	0.5-1.5	5-7	8	10	4-10	1-1.25
Bupivacaine	0.25-0.5	2	2.5	3	15-30	2.5-6
Levobupivacaine	0.25-0.5	2	2.5	3	15-30	2.5-6
Ropivacaine	0.2-1	2-3	3.5	Not used	5-12	2.5-5

a: Maximum doses are controversial; the doses mentioned above are safe when given as single injections.

Table 2: Commonly recommended volume of injection of local anaesthetic solutions (according to patient's weight).

APPROACH	2-10 kg	15 kg	20 kg	25 kg	30 kg	40 kg	50 kg	60 kg and above
Supra-clavicular	1 ml/kg	12.5 ml	15 ml	17.5 ml	20 ml	22.5 ml	25 ml	30 ml
Axillary	0.5 ml/kg	7.5 ml	10 ml	10 ml	12.5 ml	15 ml	17.5 ml	20 ml
Femoral (specific)	0.7 ml/kg	8 ml	12 ml	15 ml	15 ml	17.5 ml	20 ml	25 ml
Fascia iliaca	1 ml/kg	12.5 ml	15 ml	17.5 ml	20 ml	22.5 ml	25 ml	30 ml
Sciatic (lateral)	1 ml/kg	15 ml	17.5 ml	20 ml	22.5 ml	25 ml	27.5 ml	30 ml

Lumbar and Thoracic Blocks in Children: New Trends for the third Millennium

Giorgio Ivani

Regina Margherita Children's Hospital,

Turin Italy

gioivani@libero.it

Regional anaesthesia is not only a very effective approach for the intraoperative pain control, one of the best solution for reducing/suppressing the surgical stress, but, mainly, a technique for an optimal postoperative analgesia tailored to the patient's need.

Depending on the type of surgery we can choose which is the best solution for a valid analgesia and a single shot or a continuous infusion can be selected.

Before entering into details a brief anatomical description is needed.

Lumbar Level

The spinal cord ends at birth at L3 level and the inter-cristal line crosses L5. Usually the lumbar block is performed at L5-S1 or L4-L5 level with a midline approach (Taylor modified) with a Tuohy needle, almost perpendicularly to the skin with the bevel facing cephalad, crossing the superficial planes and the yellow ligament (Fig 1).

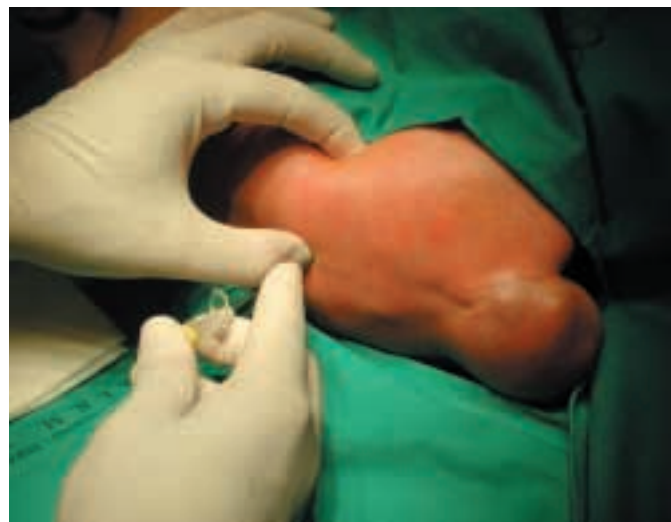

Fig 1: Approaching the lumbar level in a newborn (a big sacral teratoma can be seen)

The Loss of Resistance Technique (LOR) can be performed with air or with saline solution or CO₂ (1). In Italy we are used to work with air. Moreover air may be useful in newborns or infants to detect if dura mater was accidentally punctured (saline solution may mask CSF reflux that at this age has not the usual adult pressure) and saline can dilute the small amount of drug used. We use 1-1.5 ml of air just to detect the change of resistance and not to inject into the epidural space. (Fig 2)

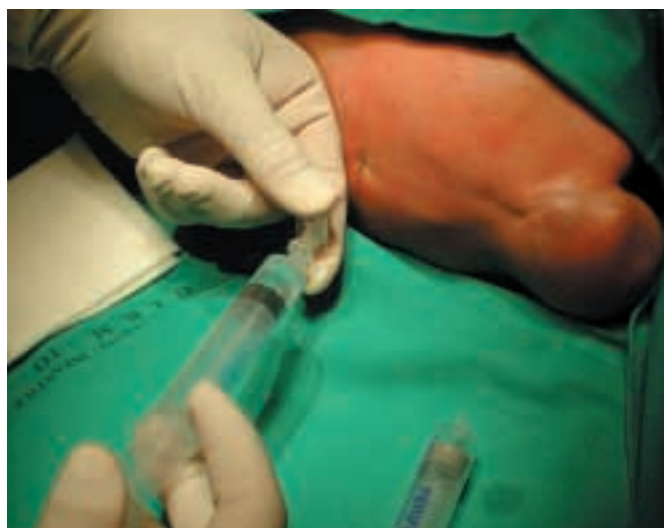

Fig 2: Detecting the epidural space

The indications for the lumbar block are operations involving dermatomes between T5 and S5, single shot for surgery lasting less than 90 min and with no need for long post-operative analgesia

Thoracic Level

The anatomy of the thoracic approach increases the difficulty in the block performance because the spinous processes are more oblique than at lumbar level, the epidural space is reduced and the dura mater is much closer to the yellow ligament and the spinal canal is narrower. We have to balance the risk/benefit ratio and only well-trained, experienced anaesthetists must approach this block

The landmarks are the prominent spine of the 7th cervical vertebra and the line joining the angles of the shoulder blades that crosses the 7th thoracic vertebra. The Tuohy needle must be inserted with a more oblique inclination; the median approach is preferable and, as usual, a sedation/light anaesthesia is mandatory before the block performance.

Indications: T2-T4 level for the thoracic surgery, T6-T8 level for upper abdominal surgery and T10-T12 for lower abdominal surgery.

Continuous infusion or single shot?

The decision if a single shot or a continuous infusion must be performed depends on the length of surgery and on the intensity of postoperative pain. A procedure can

be very short but very painful too, even in the postoperative period or may be very longlasting so that a single shot cannot provide adequate analgesia along the operation itself.

Generally speaking for the so called "minor surgery" such as inguinal hernia, hydrocele, phymosis the analgesic requirement is reduced and a single shot is the best solution while for a long term surgery a catheter positioning is advisable.

Continuous epidural catheter placement

When a catheter positioning is required, even if there are reports about the placement of an epidural catheter at lumbar or thoracic level from the caudal space, Tuohy needle should be inserted in the correct site, close to the surgical target area, with the indwelling catheter just 2-3 cm in the epidural space in order to avoid postoperative infusion of excessive drug doses or kinking or malpositioning. Moreover, as case reports describe infections or colonizations after catheterisation "if catheter is supposed to be maintained after the end of surgery for the postoperative pain control, the lumbar approach seems to have less risks than the caudal one (2-7)".

Drugs and tools.

A single local anaesthetic has been used for years and even for a long acting drug such as bupivacaine the analgesic duration was limited to 4-5 h. Today we have safer drugs such as ropivacaine and levobupivacaine, enantiomers whose cardio and nervous toxicity are reduced but, in terms of duration their action is very similar to bupivacaine (8-14).

The multimodal approach has been established using either different routes together (i.e. epidural plus i.v. or oral and in that way a single shot combined with an i.v. infusion of NSAIDs can be effective) or different drugs with an additive/synergistic action along the same route. Recently it has been demonstrated that the use of adjuvants can prolong the action of the local anaesthetics. Morphine or better ketamine and clonidine are able to double the analgesic duration (15-18).

In this way a single shot performed with ropivacaine or levobupivacaine plus clonidine can last 8-9 h and a simple administration of paracetamol is then sufficient to cover all the overnight period for minor surgery.

Also for a continuous infusion anyway the use of multiple drugs reduces the toxicity of each drug and increases the analgesic effect: for instance an infusion of 0.1% ropivacaine 0.4 mg/kg/h plus clonidine 3 mcg/kg/24h gives a satisfactory and uneventful postoperative period (19).

Another important step forward in this new century is given by **the availability of adequate material**; many congenital malformations such as atresia ani, gastroschisis etc require immediate surgery and it means long term operations in newborns, a ICU postoperative period which must be painless and as short as possible.

The use of regional anaesthesia in these cases represents the best solution; obviously a single shot is not sufficient and a continuous infusion is needed. The problem was connected for years to the age and the dimensions of the small patient: today we can cope with and solve this problem thanks to adequate tools: Very short and small Tuohy needles, small but safe catheters are now available and

we can perform a block and a catheter positioning even in very low weight newborns so that also in the paediatric field the accelerated program and the outcome improvement can be applied.

Of course what is needed for a continuous infusion is mandatory for a single shot too, both at lumbar or thoracic level and even the caudal approach requires the appropriate size and needle, short bevelled and with a stylet inside (20).

In conclusion pain control is one of the main targets in children and it is a big challenge for the new century.

Today we, paediatric anaesthesiologists, have many opportunities to work in a safe and effective way for an adequate pain control and with drugs such as ropivacaine and levobupivacaine, adjuvants such as clonidine and ketamine and paediatric tools such as small Tuohy and caudal needles and catheters, regional anaesthesia can be considered one of the best solution playing a great role in the perioperative pain management. (21-22)



Fig 3: Save lumbar placement of the Perifix® Paed epidural catheter through the Perican® Paed Tuohy needle.



Fig 4: Perican® Paed Tuohy type epidural needles

References

1. Scott DB Identification of the epidural space: loss of resistance to air or saline? . Editorial. *Reg Anesth* 1997; 22(1):1-2
2. Bosenberg AT, Wiersma R, Hadley GP. Oesophageal atresia: caudo-thoracic epidural anesthesia reduces the need for postoperativeventilatory support. *Pediatr Surg Int* 1992; 7:289-291
3. Gunter JB, Eng C. Thoracic epidural anesthesia via the caudal approach in children. *Anesthesiol* 1992; 76:935-938
4. Emmanuel ER. Post-sacral extradural catheter abscess in a child. *Br J Anaesth* 1994; 73:548-549
5. Meunier JF, Noorwood P, Dartayet B et al. Skin abscess with lumbar catheterization in infants: is it dangerous? Report of two cases. *Anesth Analg* 1997; 84:1248-1249
6. Strafford MA, Wilder RT, Berde CB. The risk of infection from epidural analgesia in children: a review of 1620 cases. *Anesth Analg* 1995; 80:234-238
7. McNeely JK, Trentadue NC, Rusy LM et al. Culture of bacteria from lumbar and caudal epidural catheters used for postoperative analgesia in children. *Reg Anesth* 1997; 22(5):428-431
8. Ivani G, De Negri P New Insights into Paediatric Regional Anaesthesia: New Drugs. *Curr Opin Anaesth* 2001; in press
9. Ivani G, Lampugnani E, Torre MA et al Comparison of ropivacaine with bupivacaine for paediatric caudal block. *Br J Anaesth* 1998; 81:247-248
10. Ivani G, Lampugnani E, DeNegri P et al. Ropivacaine vs bupivacaine in major surgery in infants. *Can J Anaesth* 1999; 46:467-469
11. Morton NS. Ropivacaine in children. *Br J Anaesth* 2000; 85:344-346.
12. Da Conceicao MJ, Coelho L. Caudal anaesthesia with 0.375% ropivacaine or 0.375% bupivacaine in paediatric patients. *Br J Anaesth* 1998; 80:507-508
13. Gunter JB, Gregg T, Varughese AM, et al. Levobupivacaine for ilioinguinal/iliohypogastric nerve block in children. *Anesth Analg* 1999; 89: 647-9
14. Ivani G, DeNegri P, Conio A et al. Levobupivacaine vs Ropivacaine vs Bupivacaine in paediatric caudal anaesthesia. *Anesthesiology* 2001. ASA suppl. in press
15. Ivani G, De Negri P, Conio A et al Ropivacaine-Clonidine combination for caudal blockade in children. *Acta Anaesth Scand* 2000; 44:446-449
16. Koinig H, Marhofer P, Krenn CG et al. Analgesic effects of caudal and intramuscular S(+)-ketamine in children. *Anesthesiology* 2000; 93:976-980.
17. Lee HM, Sanders GM. Caudal ropivacaine and ketamine for postoperative analgesia in children. *Anaesthesia* 2000; 55:806-810.
18. De Negri P, Ivani G, Visconti C et al How to prolong postoperative analgesia after caudal anaesthesia with ropivacaine in children: S-ketamine vs clonidine. *Paediatr Anaesth* 2001; in press
19. De Negri P, Ivani G, Visconti C et al. Dose-response relationship for clonidine added to a postoperative continuous epidural infusion of ropivacaine in children. *Anesth Analg* 2001; 93:71-76
20. Broadman LM. Where should advocacy for pediatric patients end and concerns for patient safety begin?. *Reg Anesth* 1997; 22: 205-208
21. Ivani G, Conio A, Papurel G et al. 1000 consecutive blocks in children: how to manage them safely. *Region Anesth Pain Med* 2001; 26:93-94
22. Giaufre E, Dalens B, Gombert A. Epidemiology and morbidity of regional anesthesia in children. A one year prospective survey of the french language society of pediatric anesthesiologists. *Anesthesia and Analgesia*. 1996; 83:904-912

B | BRAUN
HOSPITAL CARE

B. Braun Melsungen AG
P.O. Box 11 20
D-34209 Melsungen

Tel +49 (56 61) 71-0
Fax +49 (56 61) 71-45 55
www.bbraun.com