


B. Braun Sutures

Knotting & Suturing Techniques

An overview on current techniques
for knotting and suturing



Learn how to knot and suture with
your partner in surgery



Contents

A. Introduction

- **Introduction**A1
- **Surgical instruments**A2
 - Scalpel
 - Dissecting forceps
 - Scissors
 - Needle holder
 - Haemostats (artery forceps)
 - Haemostats' & needle holder's lock
- **Sutures**A3
 - Thread variability
 - Needle variability
 - Holding the needle

B. Knotting techniques

- **Knots at a glance**B1
- **Square knot**
(Two-hand technique)
 - First throwB2
 - Second throwB3
- **Square knot**
(One-hand technique)
 - First throw (index-finger tech.) .B4
 - Second throw (middle-finger tech.) .B5
- **Granny knot**B6
- **Surgeon's knot**
 - First throwB7
 - Second throwB8

- **Surgeon's knot**
(Alternate technique)
 - First throwB9
 - Second throwB10
- **Square knot with instrument** ...B11
- **Surgeon's knot with instrument** ..B12
- **Deep tie**B13
- **Sliding knot**B14
- **Ligation around**
haemostatic clamp
 - Common techniqueB15
 - Alternate techniqueB16
- **Self Locking Knot**B17

C. Suturing techniques

- **Subcutaneous sutures**
 - SimpleC1
 - ContinuousC2
 - Continuous interlacedC3
- **Skin sutures**
 - SimpleC4
 - ContinuousC5
- **Intracutaneous sutures**
 - Non-absorbableC6
 - AbsorbableC7
- **Special sutures**
 - AllgöwerC8
 - DonatiC9
 - MattressC10
 - CornerC11

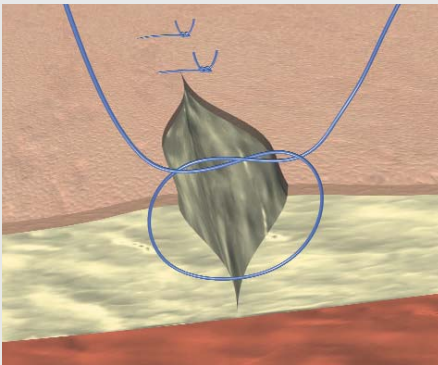
Introduction

Introduction

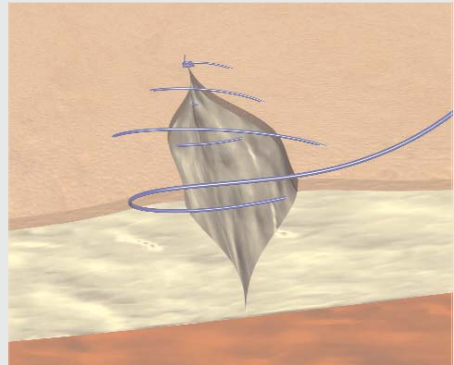
The knot to be used is not an easy election, and has to be decided according to a series of factors of which the most important are:

- The tissue or organ to be sutured.
- The depth of the wound: When the wound is located in a place of limited access, we might need a knotting technique that requires a finger or an instrument.
- The amount of tension that the wound will receive postoperatively.
- The suture's material and structure. This is an important issue, as it will determine the number of throws needed to hold the knot. Also, multifilaments are generally easier to handle and tie than monofilaments.
- The desired cosmetic result.

A number of suturing techniques have been developed over the time, and these can be divided in two main categories:



Interrupted sutures



Continuous sutures

Introduction

Depending on the tissue, the healing process, and the surgical technique and objective, the surgeon will have to choose a suture whose biological and physical characteristics are most compatible with it.

Sutures have to guarantee a firm approximation of the wound edges without an excess of tension. Only if this balance is achieved we can ensure an optimal blood circulation that will make possible an optimal healing process.

When tying, the surgeon should follow a number of basic principles:

- The knot has to be firm in order not to slip.
- Knots should be as small as possible in order to minimize the reaction to foreign body material in case of non-absorbable sutures, or to prevent an excessive amount of tissue reaction when absorbable sutures are used.
- Avoid sawing (friction between strands) of threads when tying in order not to weaken the suture.
- Avoid damage to the suture material when handling. Avoid the crushing or crimping application of surgical instruments to the strand except when grasping the free end of the suture during an instrument tie.
- The knot should not be too tight in order to allow post-operational edema and inflammation.
- Avoid excessive tension as it could break the suture or cut the tissue.
- After the first throw, enough traction should remain on one end of the strand to prevent it to loosen when tying the second throw.
- Extra knots do not add to the strength of a properly tied knot. They only contribute to its bulk.

Surgical instruments

Dissecting forceps

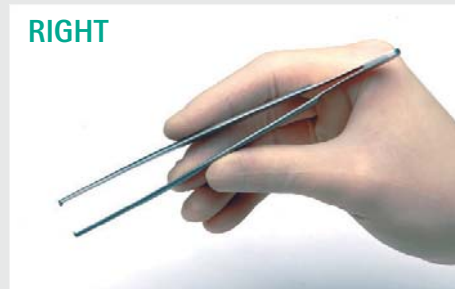There are two main types of forceps available. Toothed forceps are intended for tougher tissue such as fascia or skin, while non-toothed (atraumatic) forceps should be used for delicate tissues such as bowel and vessels.

Dissecting forceps should be used in the following manner:

1. Hold gently between thumb and fingers, the middle finger playing the pivotal role.
2. Never crush tissues with the forceps but use them to hold or manipulate tissues with great care and gentleness.



RIGHT



WRONG



Surgical Instruments

Scalpel

Scalpels are used for incising the skin, and a wide range of blade shapes and types is available depending on the tissue to be incised.

Scalpel should be used in the following manner:

1. Hold gently between index finger and thumb.
2. Incise the skin by holding the scalpel at an angle of 90° to the skin.



RIGHT

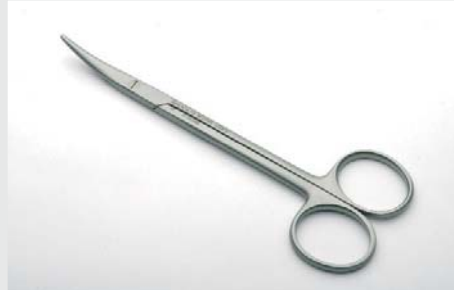

WRONG



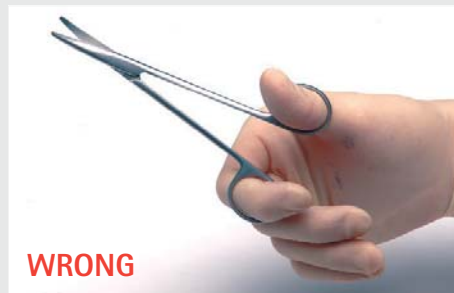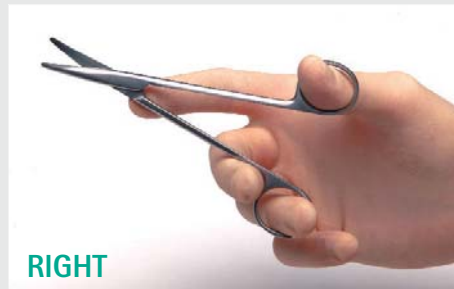Scissors

There are 2 types of scissors depending on the material to be cut. One is for soft tissues and the other is for firmer tissues such as sutures.



Scissors should be used in the following manner:

1. Insert the thumb and ring fingers into the rings of the scissors so that just the distal phalanges are within the rings.
2. Use the index finger to steady the scissors by placing it over the joint.
3. When cutting tissues or sutures, especially at depth, it often helps to steady the scissors over the index finger of the other hand.
4. Cut with the tips of the scissors for accuracy rather than using the crutch which will run the risk of damaging tissues beyond the item being divided and will also diminish accuracy.



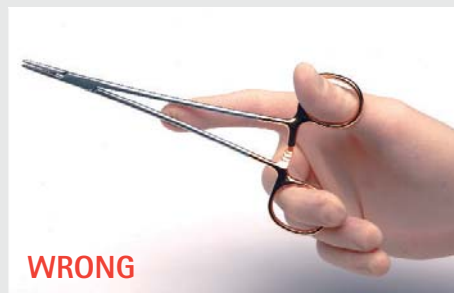
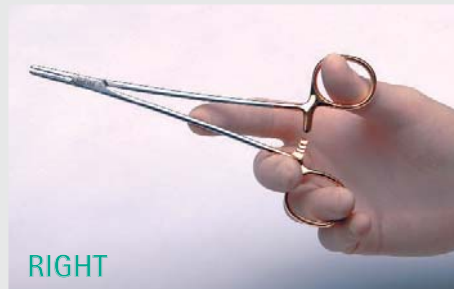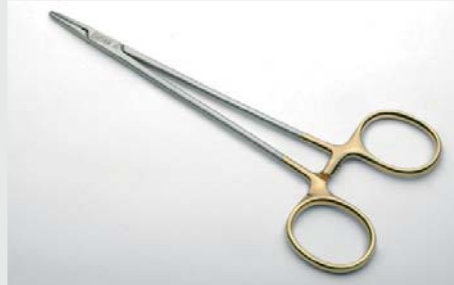Surgical instruments

Needle holder

There are different types of needle holders depending on the type of suturing. For delicate, fine suturing use a fine short-handled needle holder and an appropriate needle. Suturing at depth requires a long-handled needle holder.

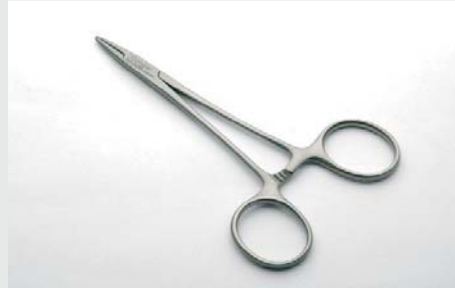The needle holder should be used in the following manner:

1. Grasp the needle holders in a similar manner to scissors.
2. Hold the needle in the tip of the jaws about two-thirds of the way along its circumference, never at its very delicate point and never too near the swaged eye.
3. Use the ratchet lock to secure the position.



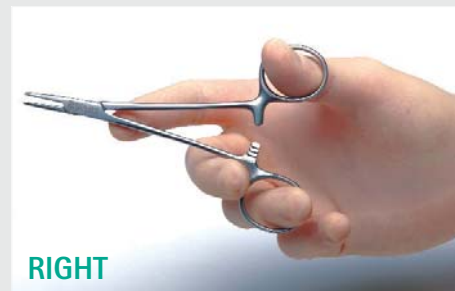
Haemostats (artery forceps)

Haemostats are used to clamp vessels that are going to be cut. The instrument will hold the vessel closed so that blood will not come out when cutting.



Haemostats should be used in the following manner:

1. Hold in a similar manner to scissors.
2. Place on vessels using the tips of the jaws.
3. Use the ratchet lock to secure the position.



Surgical instruments

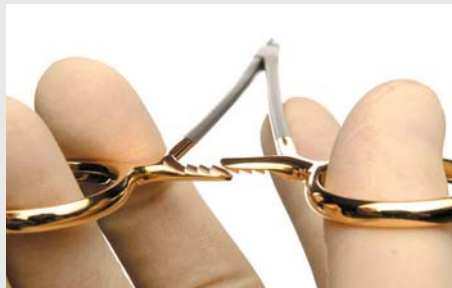Haemostats' and needle holder's lock

Haemostats and needle holders carry a security lock that surgeons should learn how to use.

Haemostats and needle holders present a security lock system to provide a firm hold.

The teathed joint will keep both arms together at a certain position when closed.

In the case of the haemostats, the surgeon should practice and learn the technique with either hand.



Gently further compress the handles and use your middle finger to separate both arms of the joint from each other.
Once both parts are separated, the instrument will be easily opened.



Sutures

Depending on the tissue to be sutured, a wide variety of sutures is available to choose from.

It is important for the surgeon to know what is available in the market regarding materials, structure, degradation profile, needle type, etc, in order to make an accurate decision.

Thread variability






Origin

According to its origin, sutures can be classified as:

- Natural origin: collagen, linen, silk.
- Metallic origin
- Synthetic origin (polypropilene, polyester, polyamide, polyglycolic acid, polyglactin, polygliconate, polydioxanone...)

Structure

According to its structure, sutures can be classified as:

- Multifilament: braided 
- twisted 
- Monofilament 
- Pseudomonofilament 
- Braided tape 

Degradation profile

And finally, according to its degradation profile, the classification will be as follows:

1. Absorbable sutures: Are absorbed in a certain period of time*.

Short-term absorbable sutures	7 days	42 days
Mid-term absorbable sutures	14-21 days	2-3 months
Long-term absorbable sutures	28-40 days	6 months
Extra-long-term absorbable sutures	90 days	13-36 months

*Orientative information

2. Non-absorbable sutures: Remain in the body forever. This includes sutures made of steel, polypropilene and polyester.
3. Pseudo-non-absorbable sutures: Lose their tensile strength in 2-3 years time. For example: silk, linen, polyamide sutures.

It is very important that the surgeon chooses an appropriate combination of these parameters, as that decision will determine many properties of the suture, such as linear/knot tensile strength, flexibility, elasticity/elongation, tissue reaction, thread surface, etc.

Not to forget is that there is no "perfect" suture as a suture being optimal on one of its characteristics will not keep position nr. 1 when considering other features.

Sutures

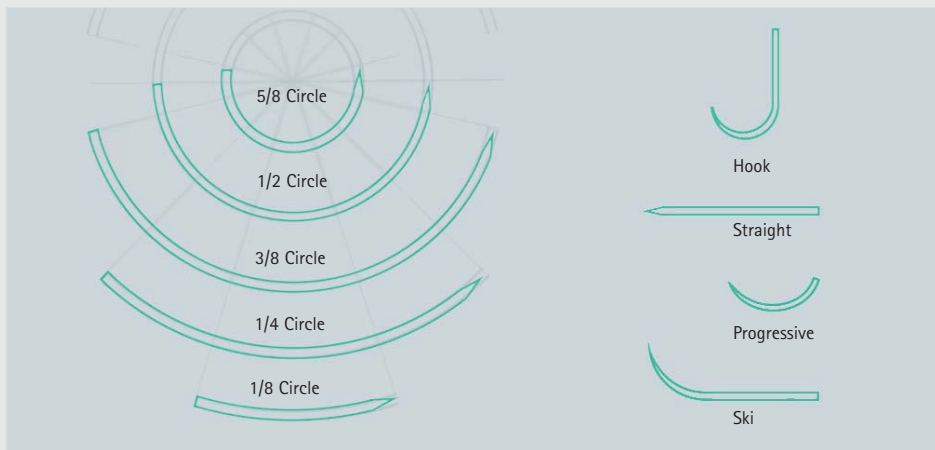
Needle variability

Different tissues need to be sutured with different suture materials. However, a factor to have constantly in mind is the needle type that we will use.

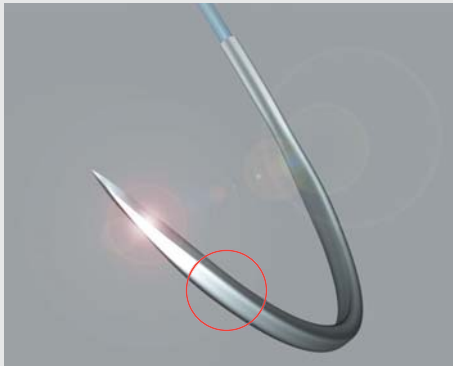
Very delicate tissues will need a completely different needle than other much stronger tissues such as tendons or even bones.

Therefore, the sutures' industry offers a wide range of needle types to choose from, being its main characteristics as follows:


- **Angle of curvature:** Needles range from straight to curved (from 1/8 circle to 5/8 circle) or partially curved (hook, ski, progressive curved...).



- **Body type:** The needle body can be round or cutting.



Round body



Reverse cutting body



Trapezoidal
micro-engraved body

- **Point type:** Blunt needles will not cut through the tissue, while sharp tips will. Then again, depending on the tissue to be sutured, the optimal point type will need to be carefully selected.

Micro-point	▽	Trocar point	⊕
Reverse cutting	▼	Taper cut	⊕
Taper point	●	Blunt point	○
Short cutting tip	⊙	Lancet	▽ ▽


Sutures

Holding the needle

Surgical needles present a specially designed body that allows a perfect hold when grasped by the needle holder. In order to avoid bending of the needle, hold it with the needle holder at $\frac{2}{3}$ of the needle length as shown in the pictures.

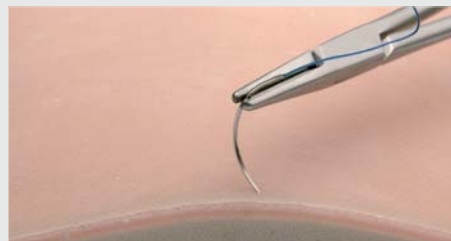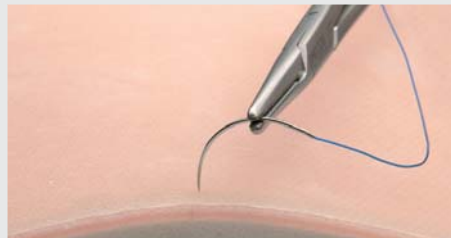


RIGHT



WRONG

When penetrating the tissues, always hold the needle tip at an angle of 90° to the tissue's surface. This will ensure the optimal hold of the tissues being sutured.

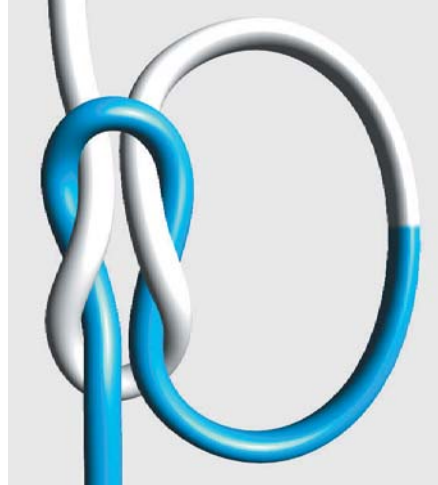


Knotting techniques

Knots at a glance




Simple knot (1)



Square knot (1=1)




Granny knot (1x1)



Surgeon's knot (2=1)

Square Knot (Two-hand technique) First throw




Square Knot (Two-hand technique) First throw


Overview




Square Knot (Two-hand technique) First throw




1
White strand over extended index finger, holding the rest of the strand in left palm.
Blue strand held with right hand.



2
Place blue strand over left thumb.



3
Approximate left index finger and left thumb.



4
Pass left thumb under white strand.




5 Place blue strand over white strand and hold it between left index finger and left thumb.



6 Use left index finger to push blue strand under white strand.

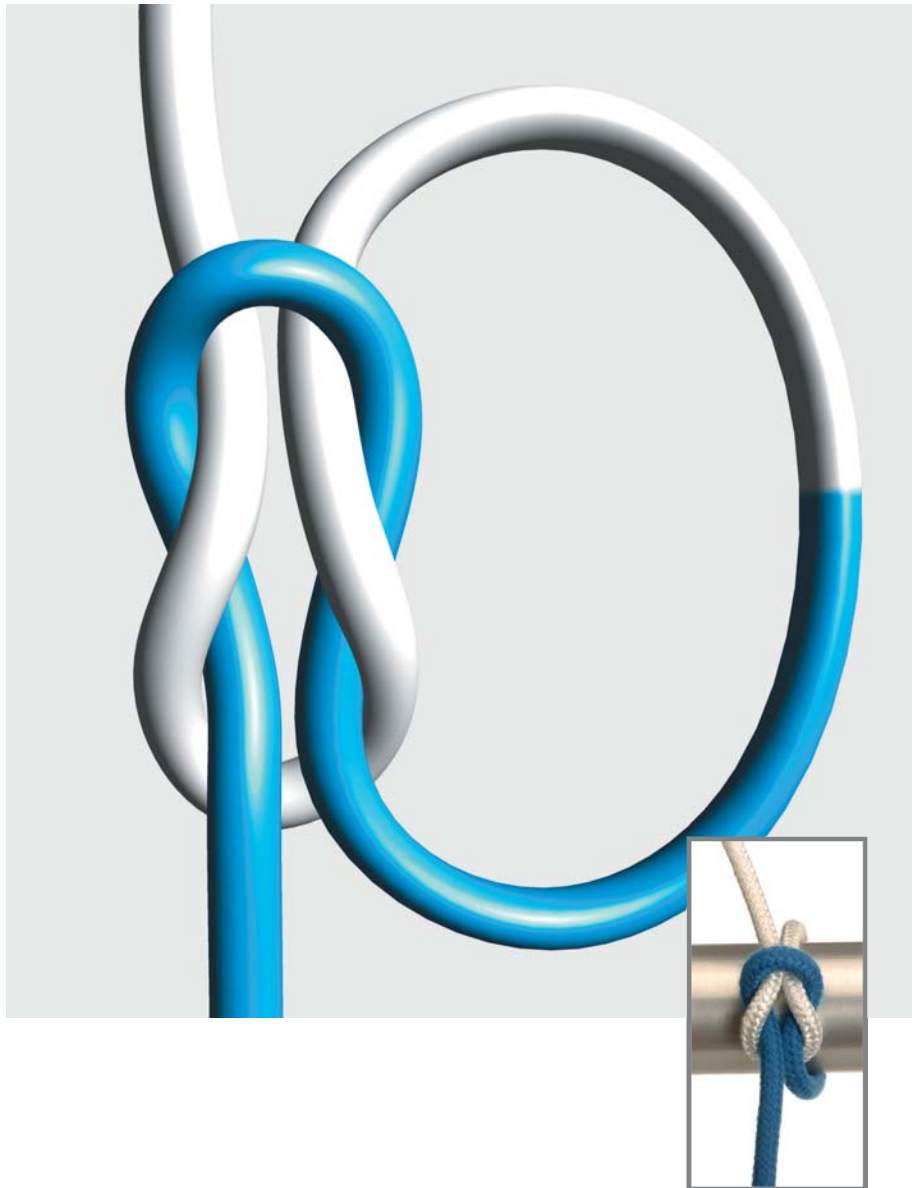


7 Pass the rest of blue strand under white strand.







8 Tighten both strands to complete the single knot.

Square Knot (Two-hand technique) Second throw



Square Knot (Two-hand technique) Second throw


Overview




Square Knot (Two-hand technique) Second throw



Starting from a single knot, place thumb over white strand while holding the rest on the strand in left palm. Blue strand held in right hand.



Place blue strand over white strand.



Approximate left index finger and left thumb.



Pass left index finger and thumb under white strand.

5



Hold blue strand between left index finger and thumb.

6



Use left thumb to push blue strand under white strand.

7



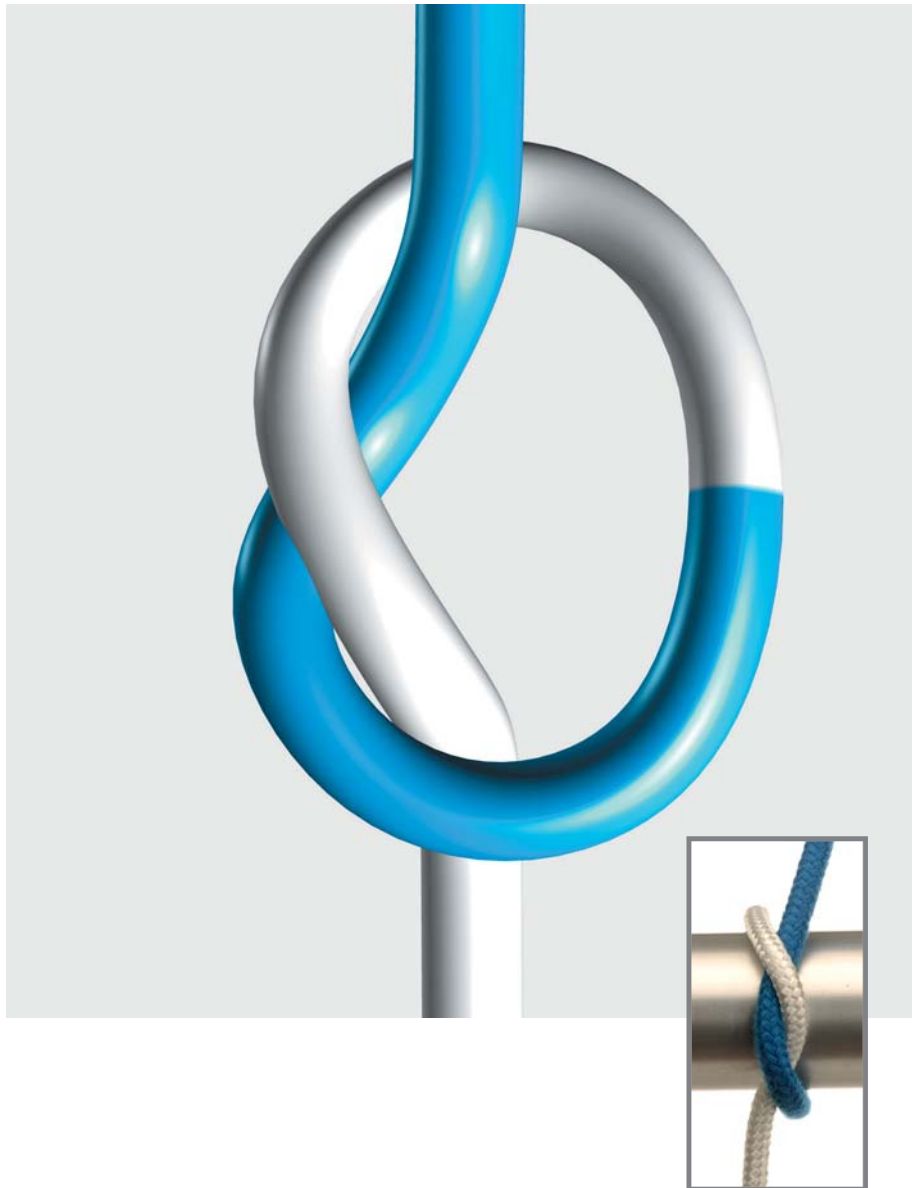
Pass the rest of blue strand under white strand.

8








Tighten both strands (white opposite to you, blue towards you) to complete a square knot.

Square Knot (One-hand technique) First throw (index-finger)




Square Knot (One-hand technique) First throw (index-finger)


Overview



Square Knot (One-hand technique) First throw (index-finger)



1 Place white strand over extended index finger of left hand, and held the rest of thread in left palm. Blue strand held in right hand.



2 Place blue strand over the tip of left index finger.



3 Place white strand over blue.




4 Pass white strand under the tip of left index finger (nail side).



Use left index finger to pull white strand under blue strand.

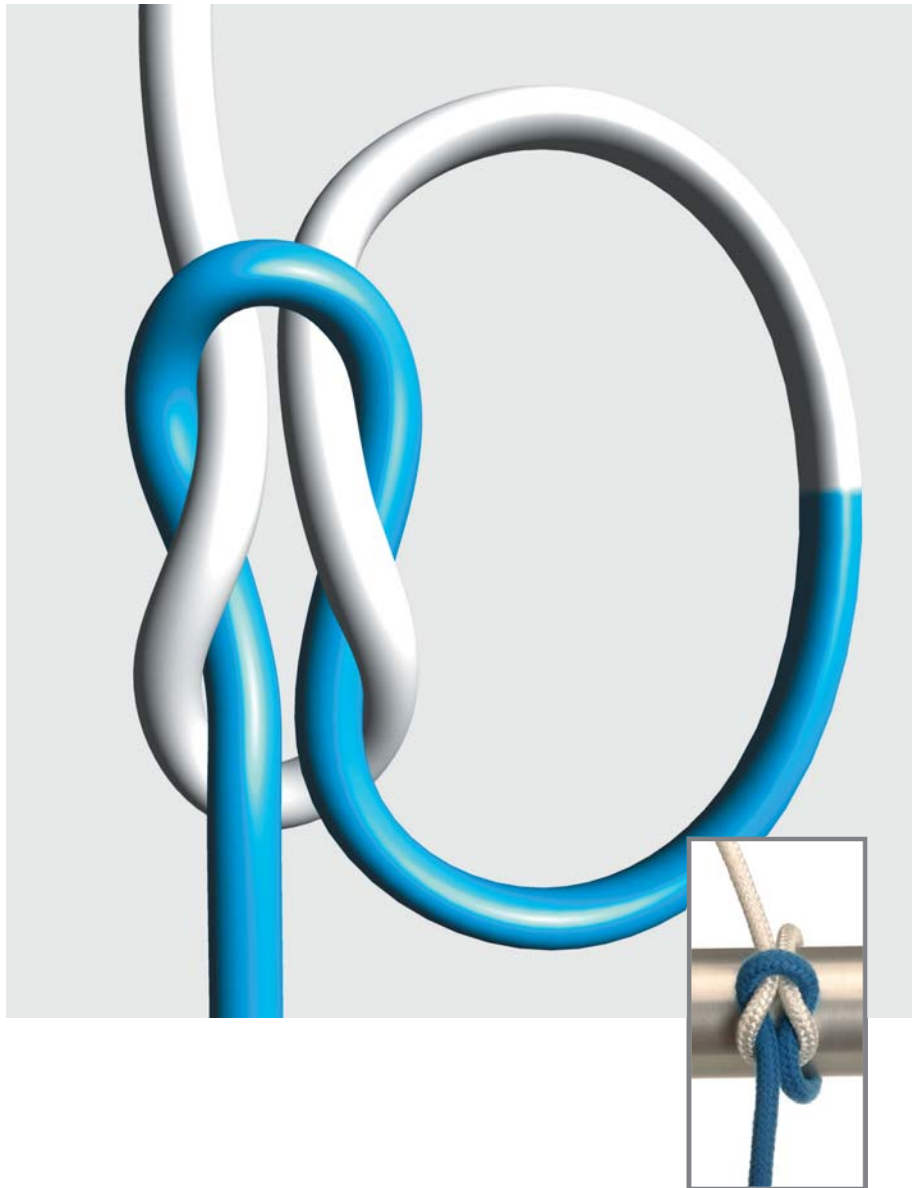


Pass the totality of white thread under blue strand.




Pull both strands in opposite directions (white down, blue up) to complete a single knot.

Square Knot (One-hand technique) Second throw (middle-finger)



Square Knot (One-hand technique) Second throw (middle-finger)

Overview



Square Knot (One-hand technique) Second throw (middle-finger)




Starting from a single knot, hold white strand as shown in picture.



Rotate left hand.



Place blue strand over middle-ring-little fingers.




Bend tip of middle finger.

5



Pass tip of left middle finger under white strand.

6




Use left middle finger to pass white strand under blue strand.

7




Pass the totality of white strand under blue strand.

8



Pull up white strand and down blue strand to complete a square knot.

Granny Knot



Special attention must be paid when tying a square knot in order to prevent that a so-called "granny" knot is obtained.

A granny knot can slip when subjected to increasing tension, and therefore must be avoided.

Please compare both carefully and study the differences between them.

Make sure that you are using the appropriate technique.



Granny knot




Square knot

My notes:

Surgeon's Knot


First throw



Surgeon's Knot


First throw

Overview



Surgeon's Knot

First throw



1
Place white strand over extended index finger of left hand. Hold the rest of the thread in left palm. Place blue strand over extended left thumb and hold rest of blue strand in right hand.



2
Approximate left index and thumb fingers.




3
Pronate left hand until thumb has passed below white strand.



4
Hold blue strand between left index finger and left thumb.



5
Push blue strand with left index finger and pass it under white strand.



6
Pass the rest of the blue strand under white strand.



Approximate left index and thumb fingers.



Pronate left hand until thumb has passed below white strand.




Hold blue strand between left index finger and left thumb.



Push blue strand with left index finger and pass it under white strand.

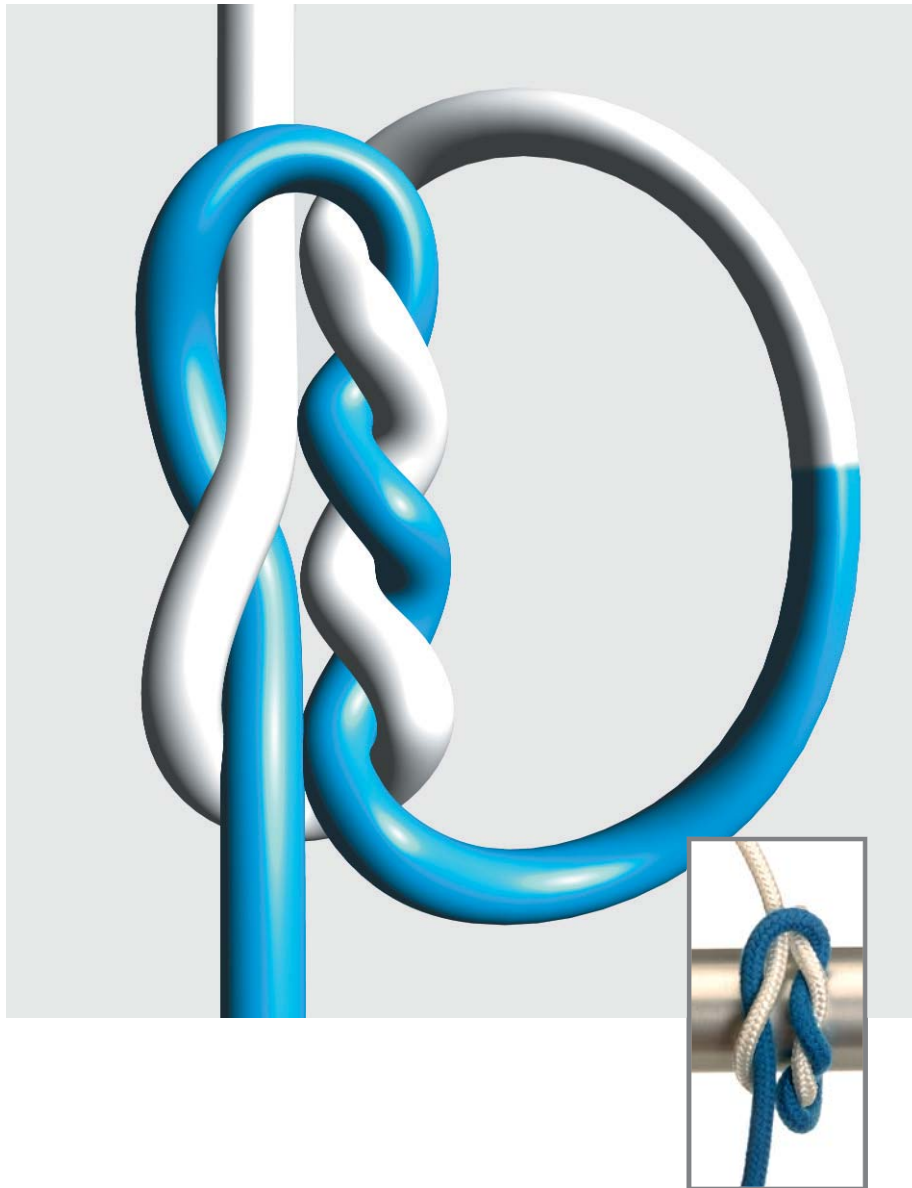


Pass the rest of the blue strand under white strand.






The first throw of a surgeon's knot should be obtained.

Surgeon's Knot Second throw




Surgeon's Knot Second throw

Overview




Surgeon's Knot

Second throw



1 Place left thumb over white strand and then place blue strand over white strand.




2 Approximate left index finger and left thumb.




3 Pass left index finger and thumb under white strand.




4 Hold blue strand between left index finger and thumb.




Use left thumb to push blue strand under white strand.



Pass the rest of blue strand under white strand and hold blue strand with right hand.




Rotate your hands and tighten both strands (white opposite to you, blue towards you).




A surgeon's knot should be obtained.

Surgeon's Knot (Alternate technique) First throw




Surgeon's Knot (Alternate technique) First throw

Overview




Surgeon's Knot (Alternate technique)


First throw




1 Hold strands as shown in the picture.




2 Rotate right hand with blue strand over little, ring, middle and index fingers.




3 Place white strand over middle, ring and little finger and parallel to blue strand.




4 Use right middle finger to pass white strand under blue strand.




5 Pass the tip of right middle finger over blue strand.



6 Extend left index finger.




Pass left index finger under the knot.



Pass tip of left index finger over white strand.




Extend left index finger and right middle finger.



Pass both strands through the loop as shown in the picture.

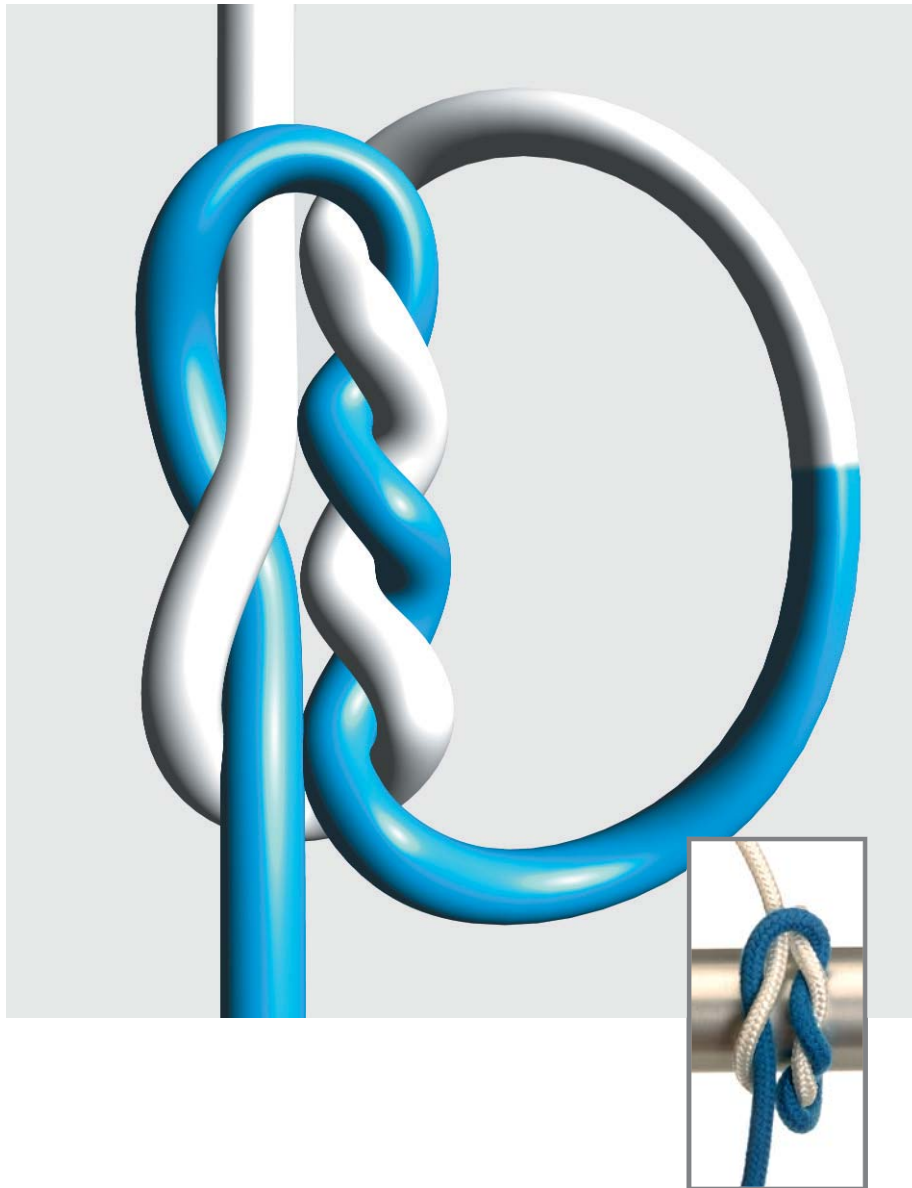


Tighten the knot by pulling blue thread away from you and white thread towards you.




The first throw on the surgeon's knot should be obtained.

Surgeon's Knot (Alternate technique) Second throw




Surgeon's Knot (Alternate technique) Second throw


Overview




Surgeon's Knot (Alternate technique) Second throw




1 Hold strands as shown in the picture.




2 Rotate right hand with white strand over little, ring, middle and index fingers.




3 Place blue strand over middle, ring and little finger and parallel to white strand.




4 Use right middle finger to pass blue strand under white strand.




Pass the tip of right middle finger over white strand.



Extend right middle finger and pass white strand under blue strand.



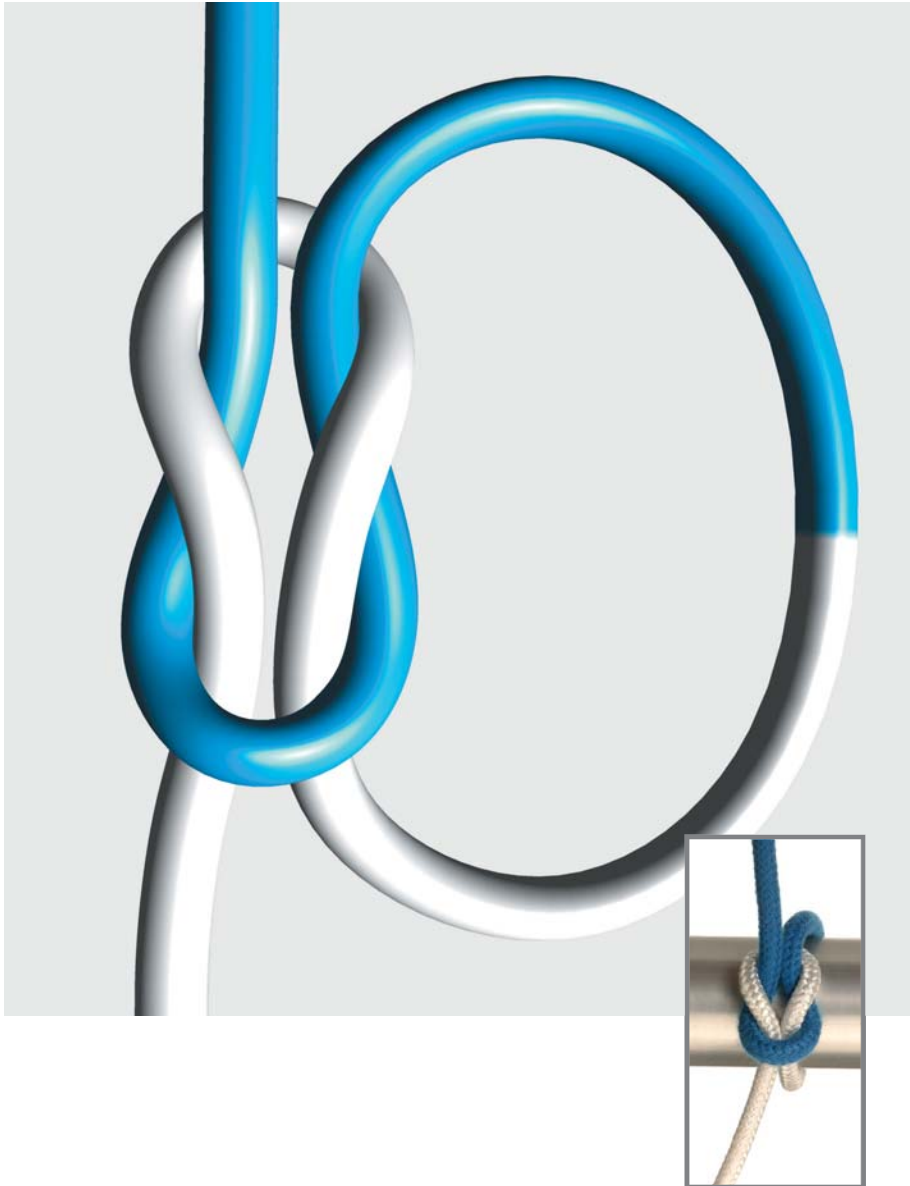
Pull white strand away from you and blue strand towards you.



A correct surgeon's knot is not completed.

Square Knot


With instrument



Square Knot


With instrument

Overview




Square Knot


With instrument




1 Place instrument over the inner surface of extended white strand.




2 Encircle instrument with white strand.



3 Grasp blue strand with instrument.



4 Pull both threads in opposite directions so that white strand pulls away and instrument pulls towards operator.



5 Place instrument again over the inner surface of extended white strand.



6 Encircle instrument with white strand.



Grasp blue strand with instrument.

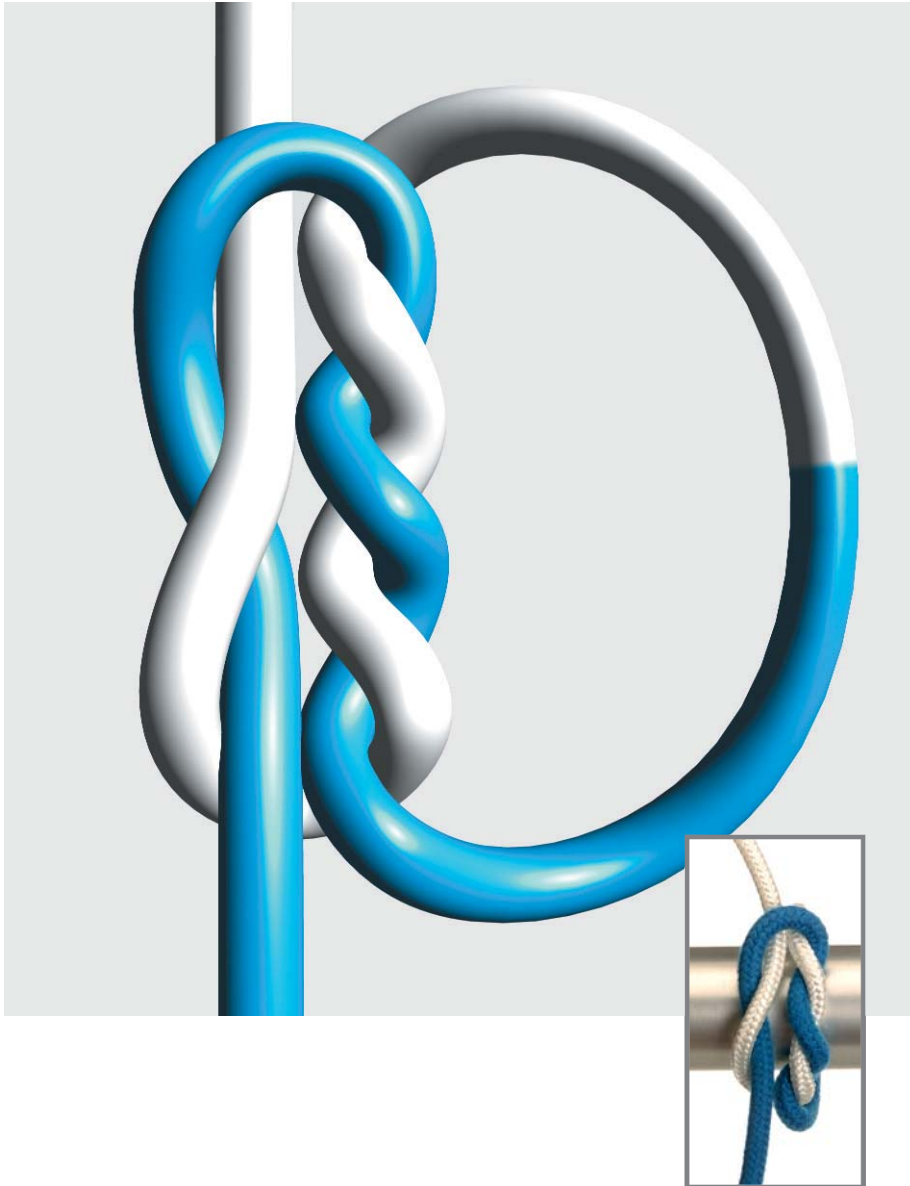


Pass blue strand through the loop formed by white strand.









Pull blue strand away and white strand towards operator. A square knot should be obtained.

Surgeon's Knot With instrument




Surgeon's Knot With instrument

Overview




Surgeon's Knot


With instrument




1 Place instrument over the inner surface of extended white strand.




2 Encircle instrument twice with white strand.




3 Grasp blue strand with instrument and pull its end through the double loop formed by white strand.




4 Pull both threads in opposite directions so that white strand pulls away and instrument pulls towards operator.




5 Place instrument again over the inner surface of extended white strand and loop white strand around instrument.



6 Grasp blue strand with instrument.




7 Pass blue strand through the loop formed by white strand.



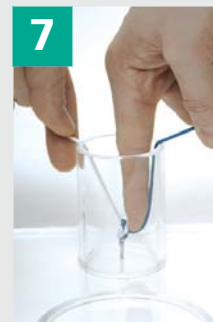8 Pull both threads in opposite directions so that instrument pulls away and white strand pulls towards operator.

Deep Tie



Deep Tie


Overview



Deep Tie



1
Tissue to be sutured lies at deep. Strands to be knotted come to the surface.



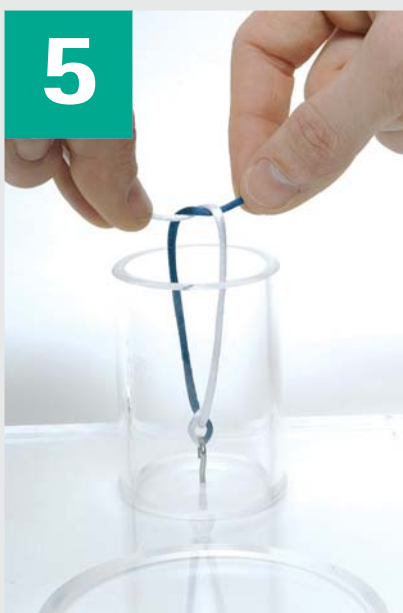2
Make a simple knot on the surface (left over right strand).



3
Use your index finger to push the knot to its final position.



4
Make sure that the knot is tight by further pushing down your index finger.



Make a second simple knot on the surface (right over left strand).




Push this second knot down in the same manner as before.



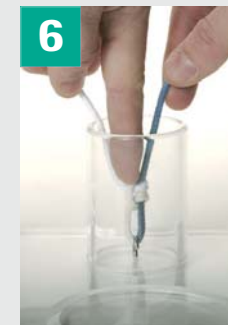


Further push down with your index finger to complete a deep square knot.

Sliding Knot




Sliding Knot


Overview



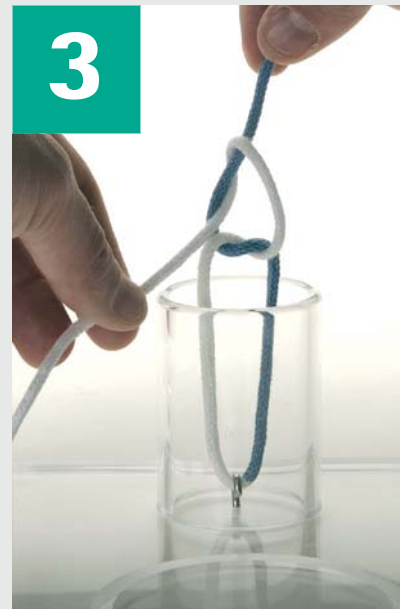Sliding Knot




Make a simple knot on the outside of the wound.



Create a square knot by adding a second simple knot. Do NOT tighten the knot.



Pull blue strand.




Blue strand held straight while white strand forms a sliding knot around it.



Tighten the knot.



Use left index finger to push the knot to its final location.




Make sure that the knot is strong enough.



Exchange strands in your hands to reobtain a square knot.

Ligation around haemostatic clamp

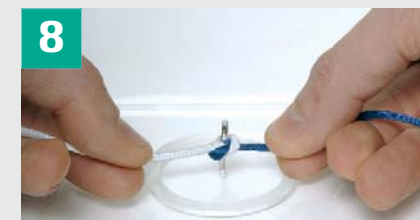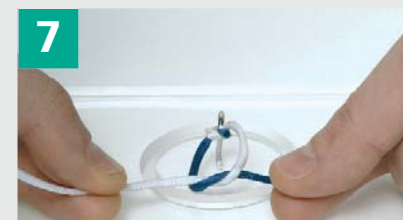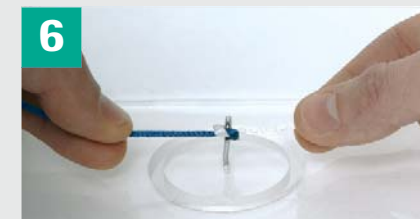

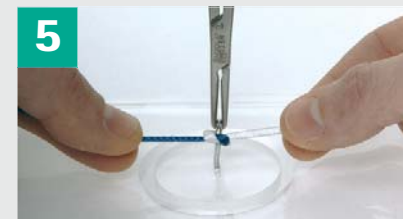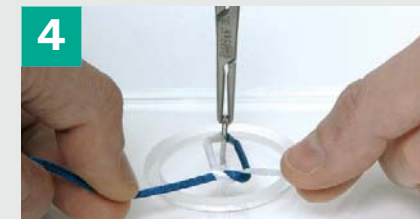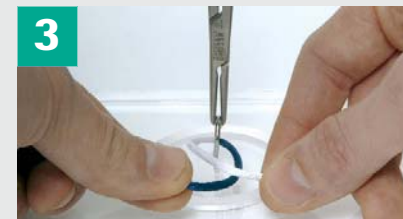Common technique



Ligation around haemostatic clamp

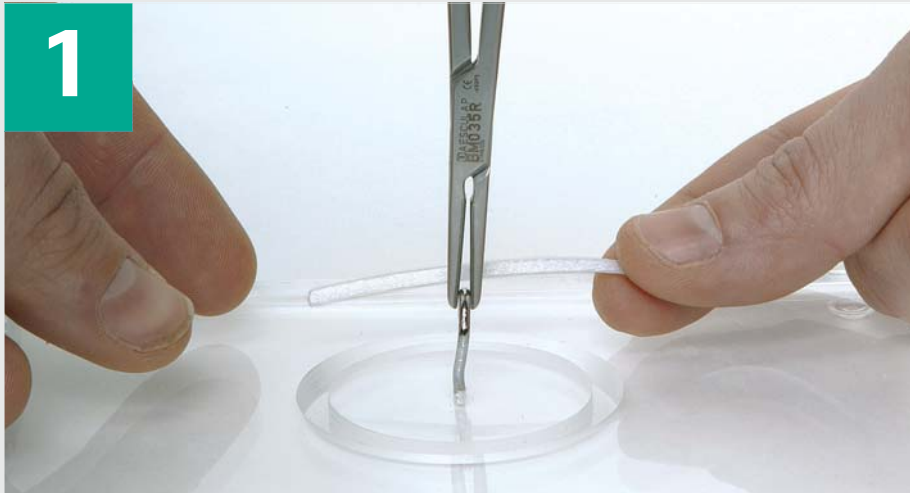
Common technique

Overview

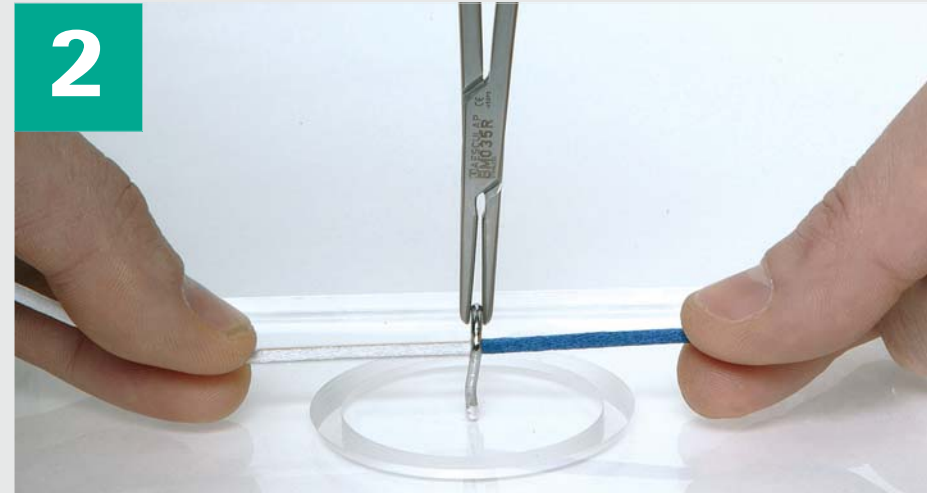


Ligation around haemostatic clamp

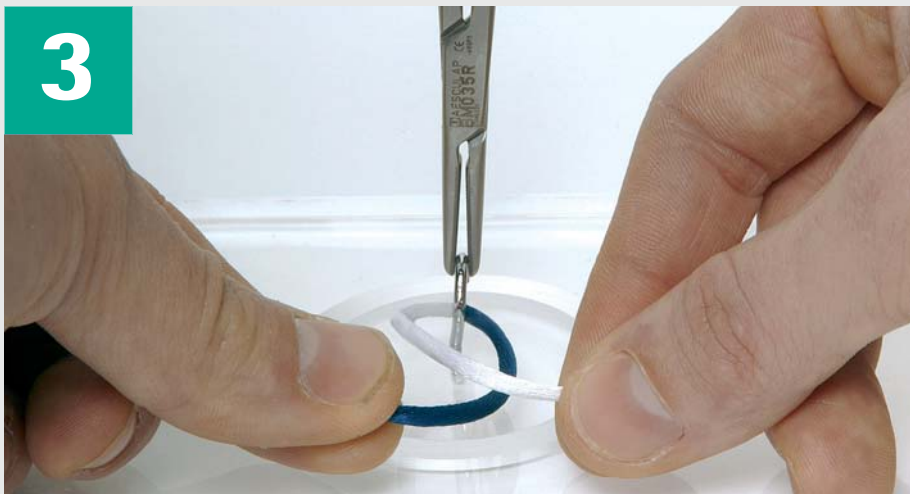Common technique



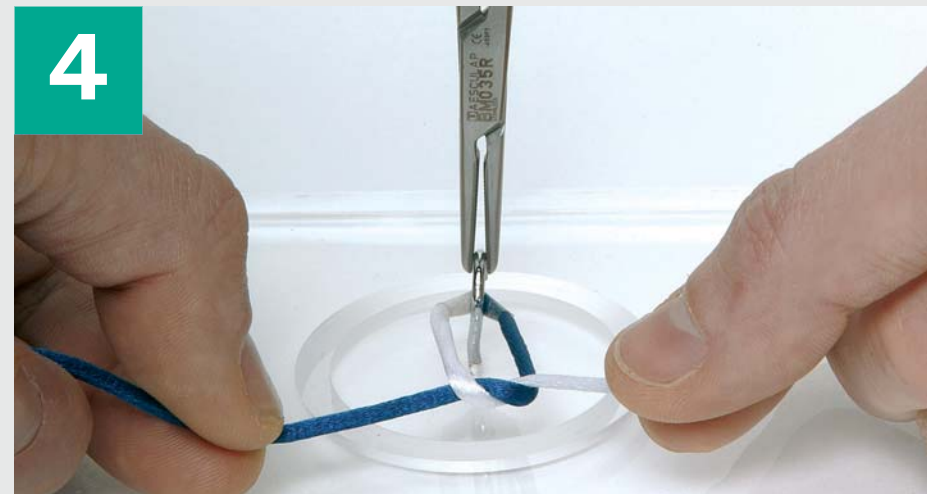
1 Pass white strand behind clamp.



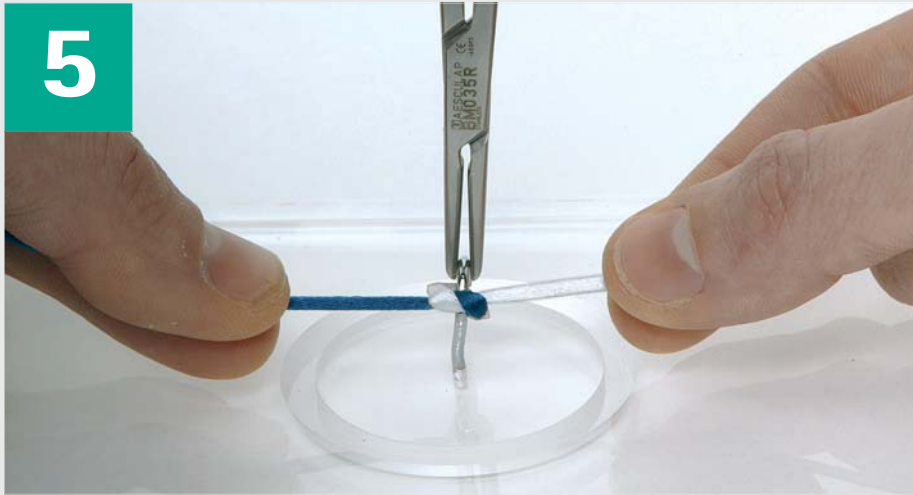
2 Grasp white end with left hand.



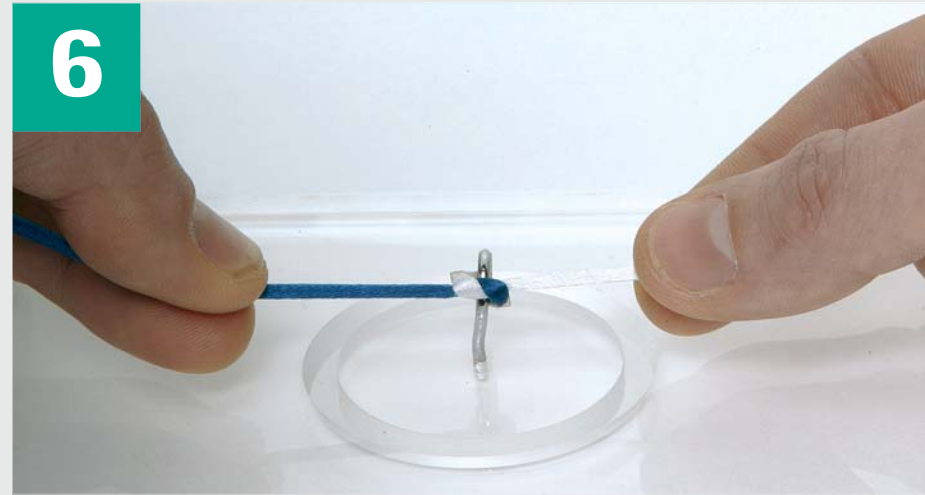
3 Place left strand over right strand.



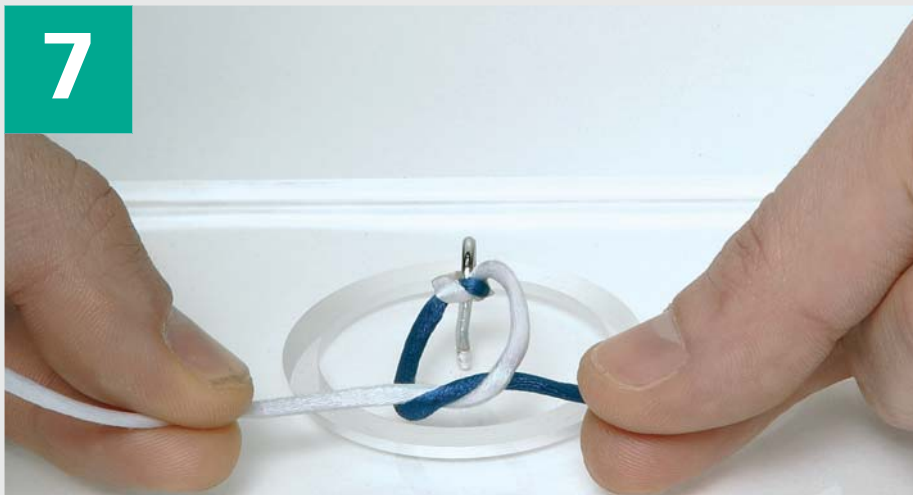
4 Perform a simple knot (left over right strand).



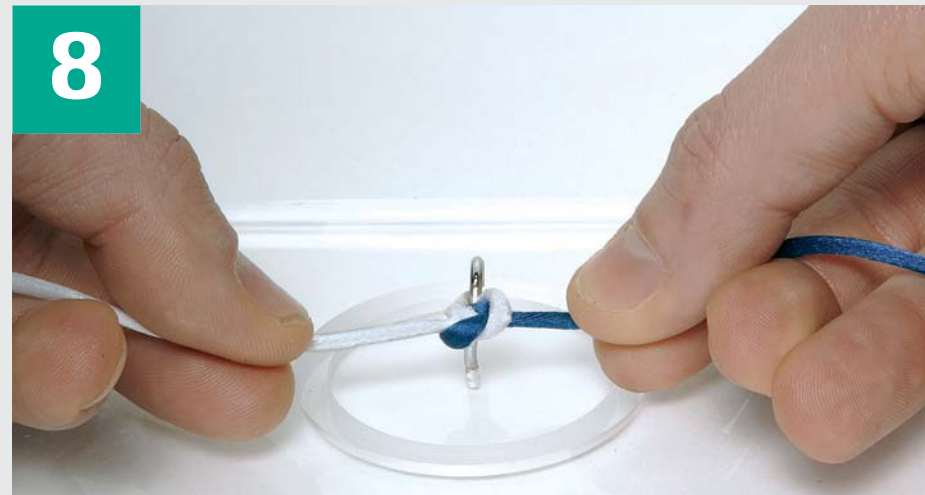Tighten the knot.



Remove haemostatic clamp.




Perform a second simple knot (right over left strand).



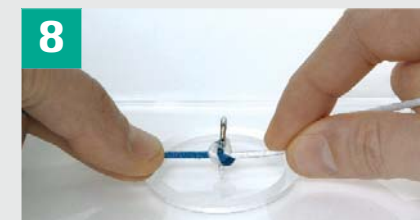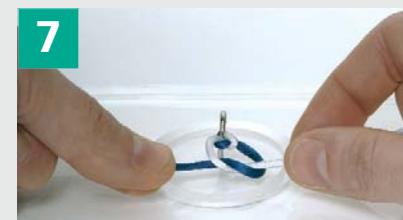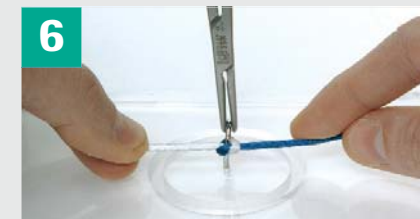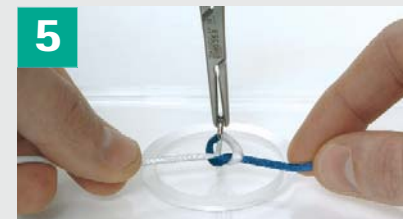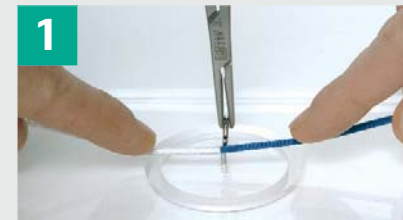
Tighten the knot to obtain a square knot.

Ligation around haemostatic clamp Alternate technique

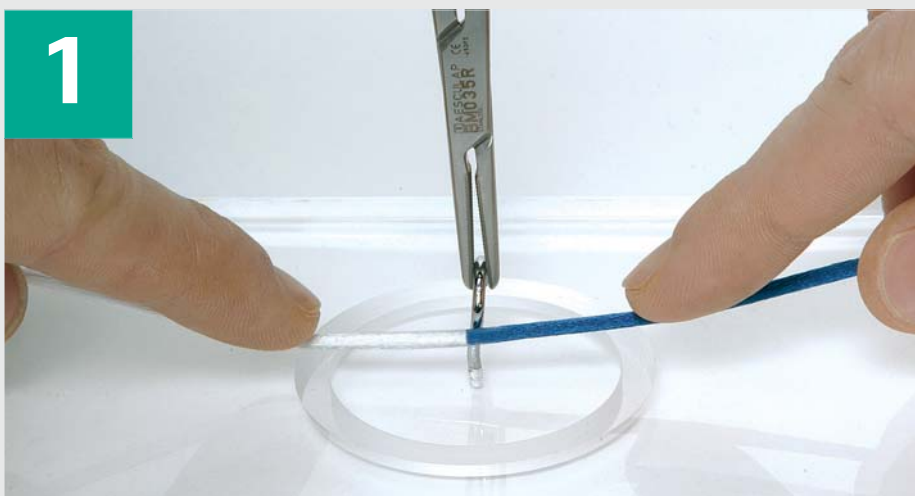


Ligation around haemostatic clamp Alternate technique

Overview




Ligation around haemostatic clamp Alternate technique



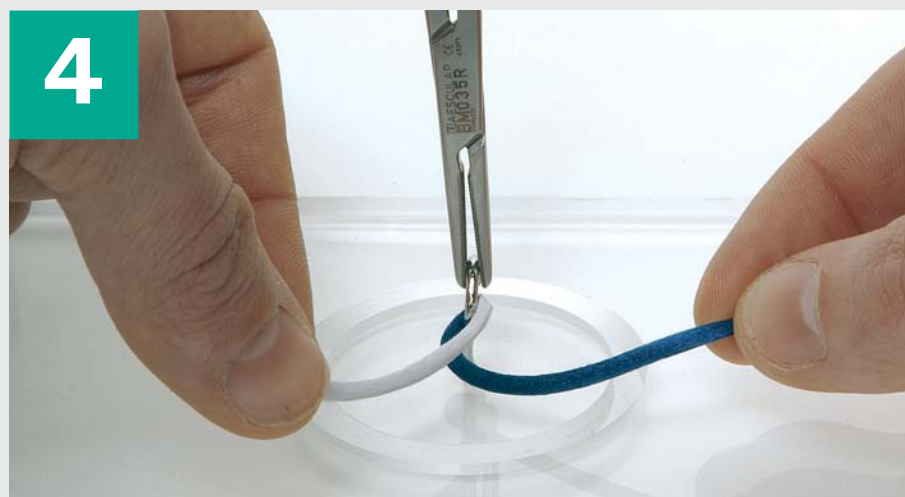1 Hold strand in front of tissue to be ligated.



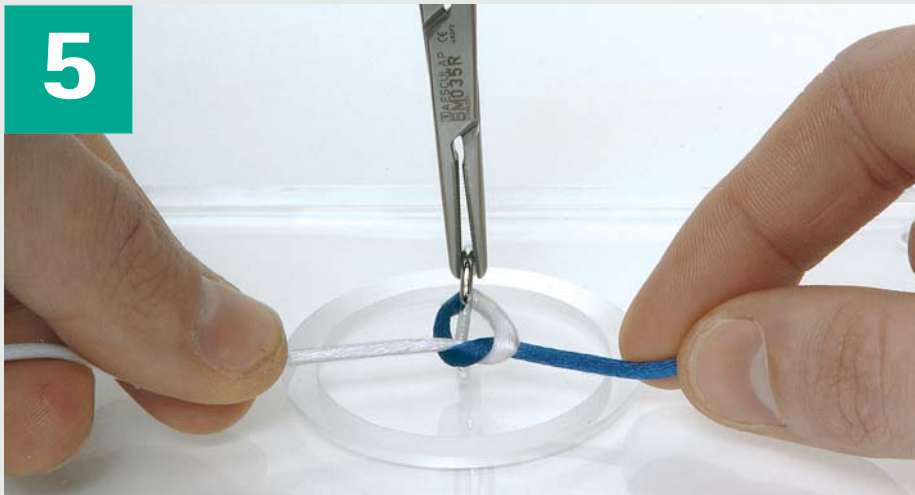
2 Use left index finger to reach blue strand.



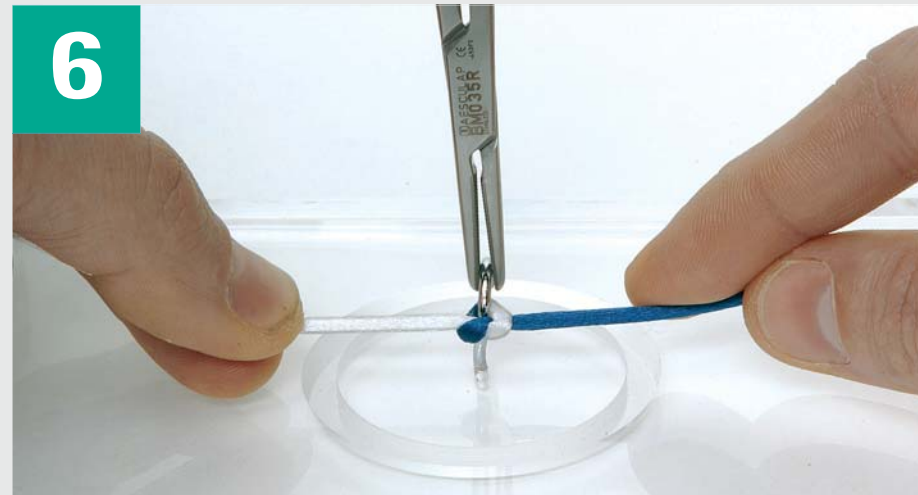
3 Approximate blue strand to white strand while holding white strand elevated.



4 Pass blue strand under white strand.



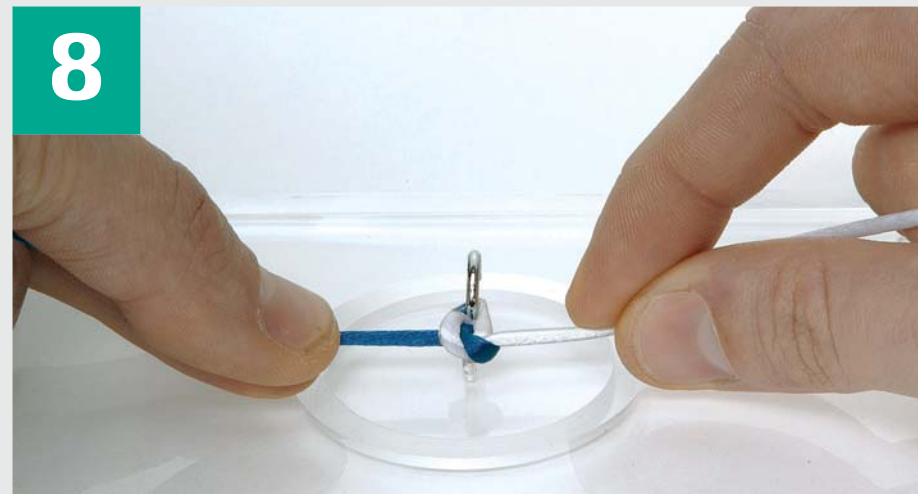
Perform a simple knot (right over left strand).



Tighten the knot.

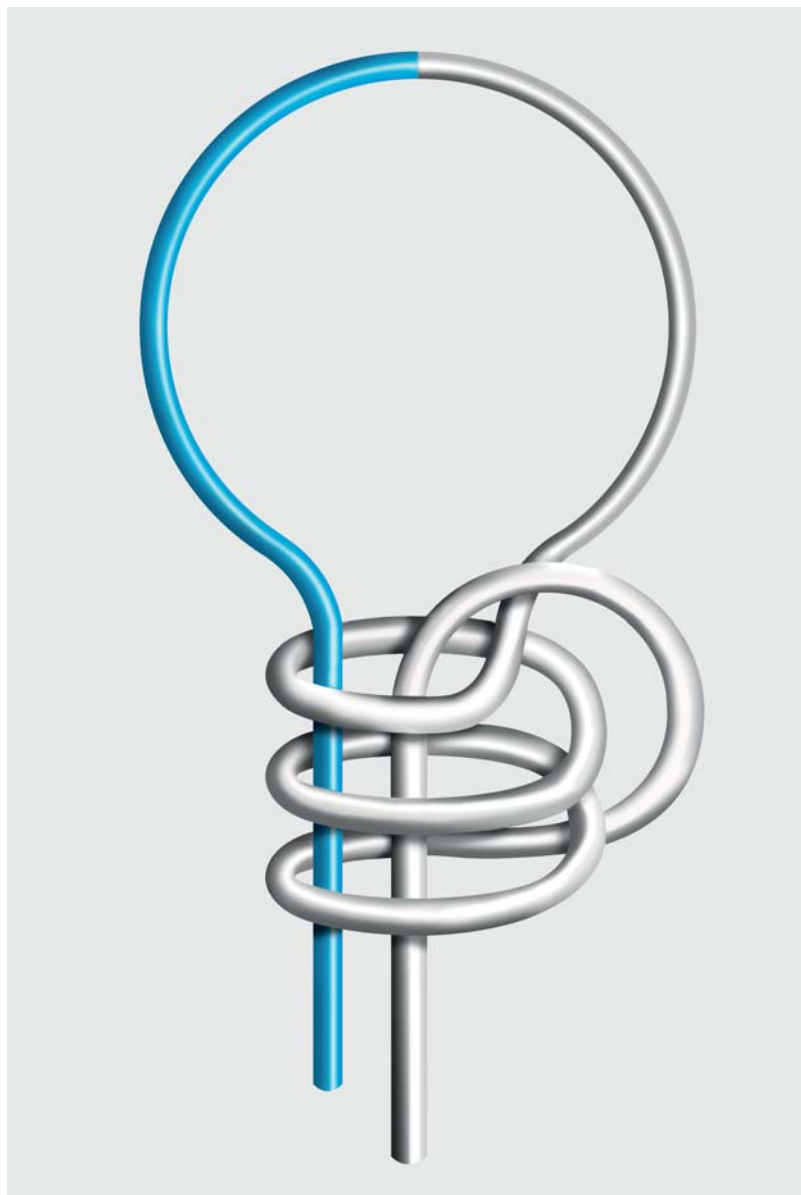


Perform a second simple knot (left over right strand).



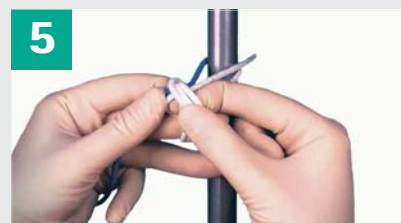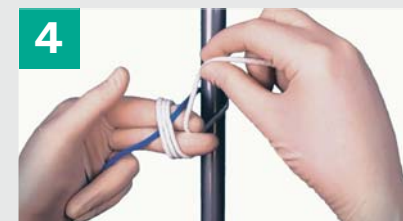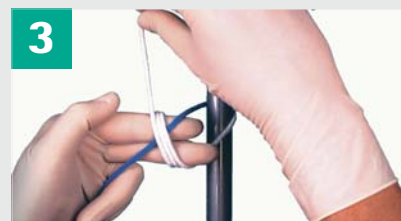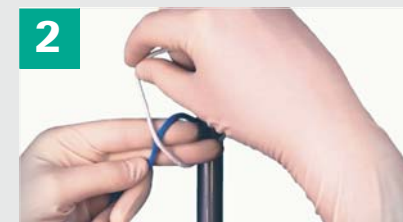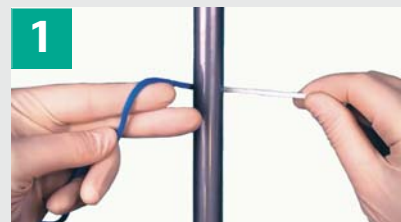
Tighten the knot to obtain a square knot.

Self Locking Knot (Two-hand technique)

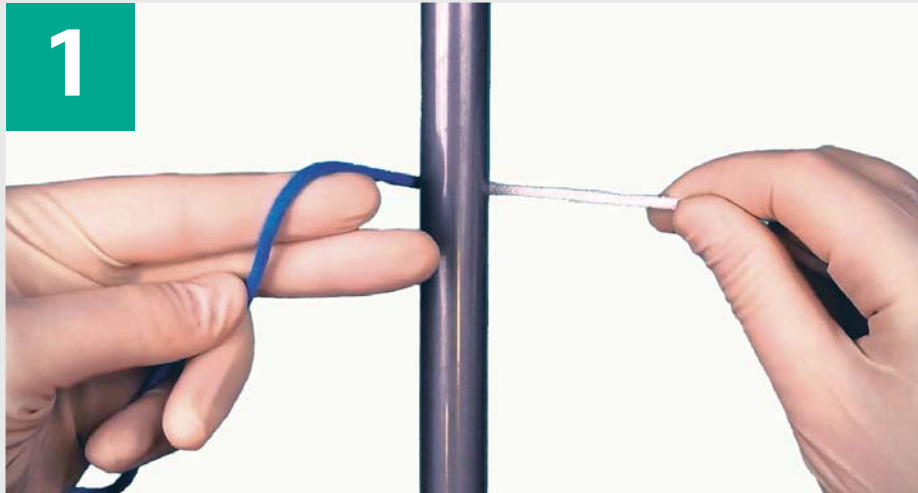


Self Locking Knot (Two-hand technique)

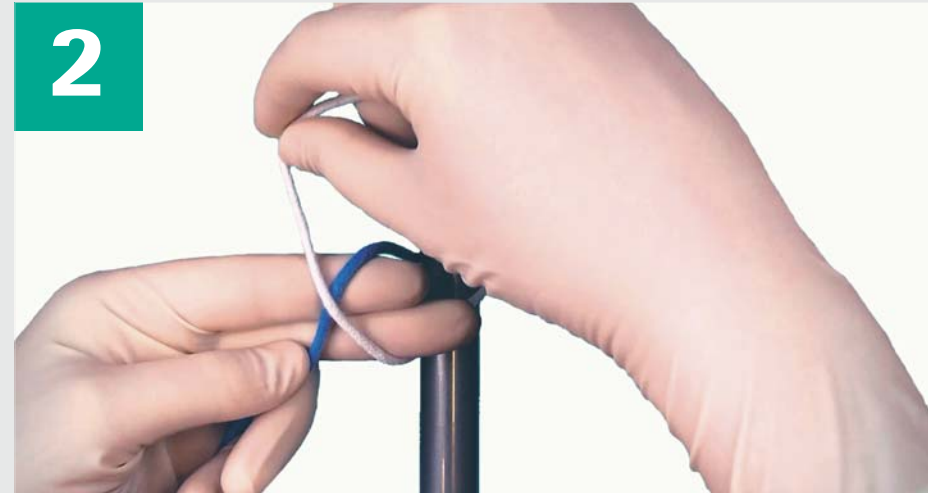Overview



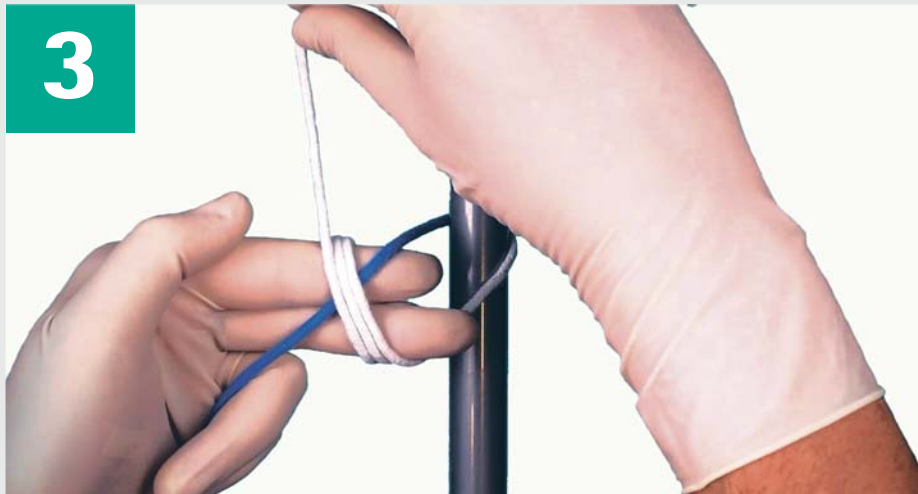Self Locking Knot (Two-hand technique) First throw



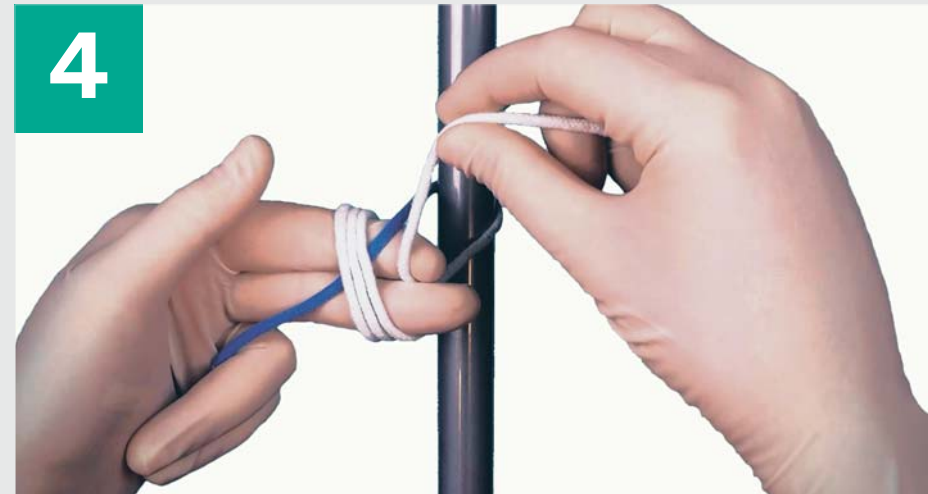
1
Place blue strand over extended index and middle finger.
White strand held with right hand.



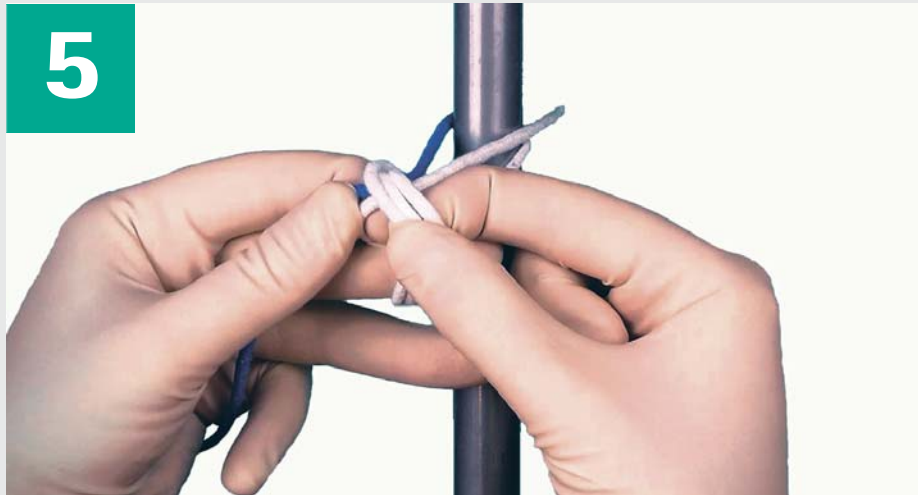2
Place white strand over left middle and index finger.



3
Wind three times white strand around left and middle finger.



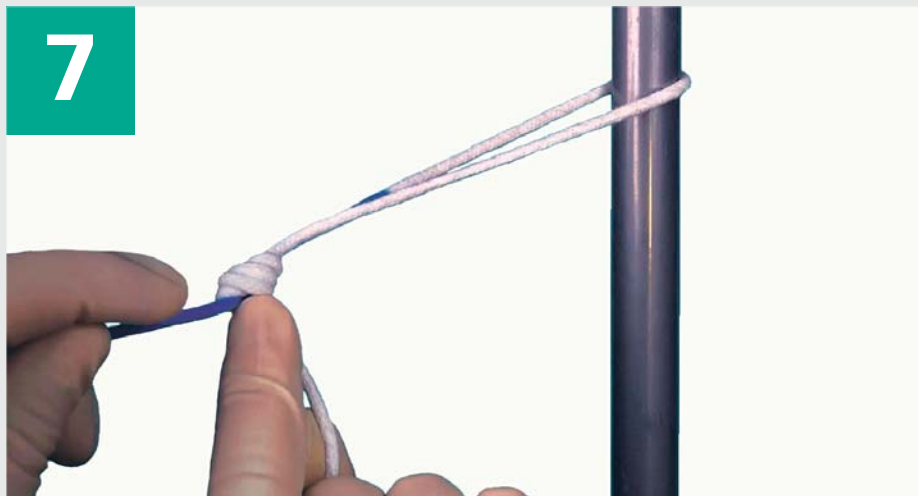4
Place white strand behind and hold it between left middle and left index finger.



Pull white strand with left hand.



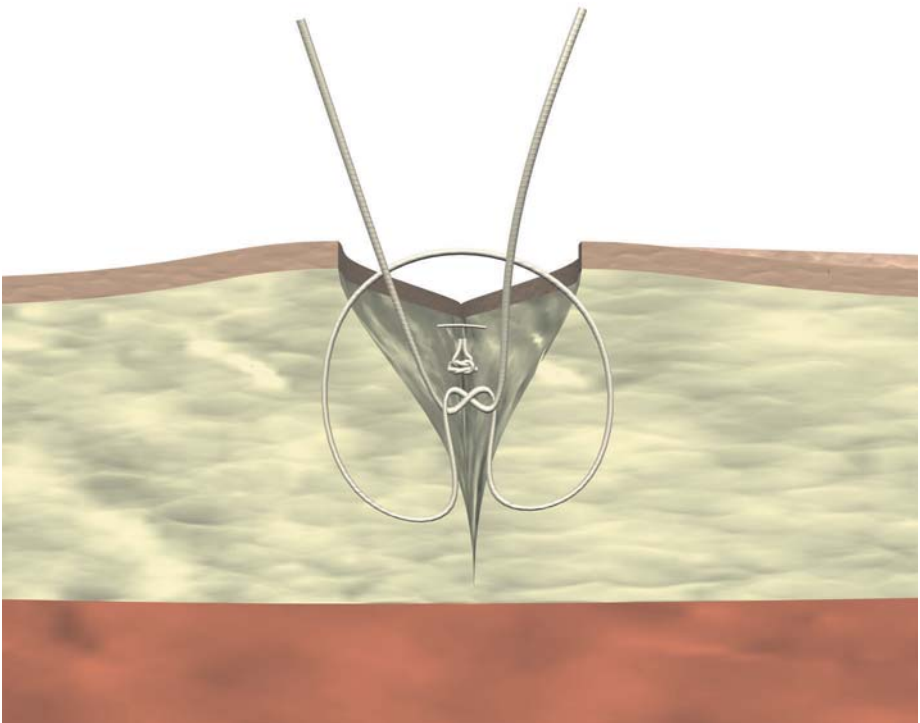
Tighten the knot.



Adjust the knot.

Suturing techniques

Simple subcutaneous suture

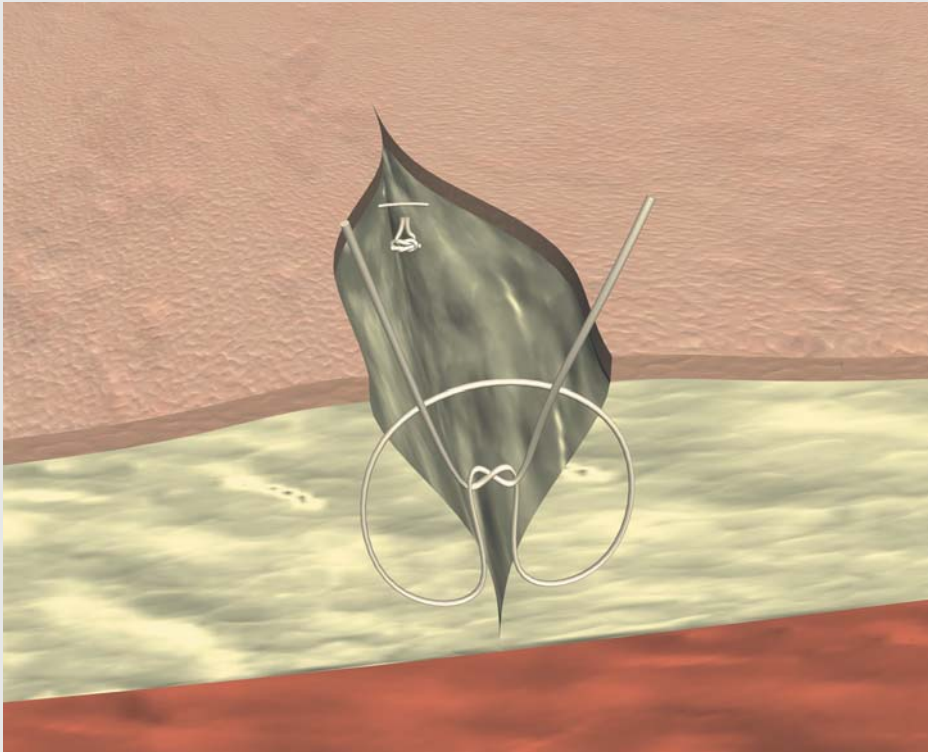


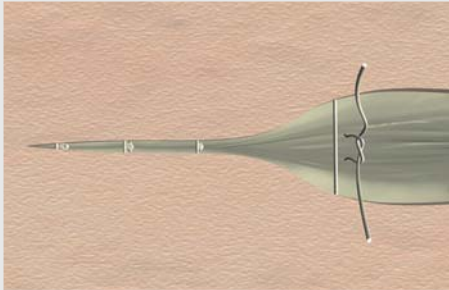
Simple subcutaneous suture

This subcutaneous suturing technique is performed to release tension from the wound surface in order to ease the healing of the skin.

Surgeon should always try to place the knots on the deeper part of the wound.

When performed in this manner, the body's reaction to the bulky knot will not take place just under the skin, and therefore the disturbance to the healing of the skin will be minimal.





Top view

This suturing technique will obtain optimal results when performed with:

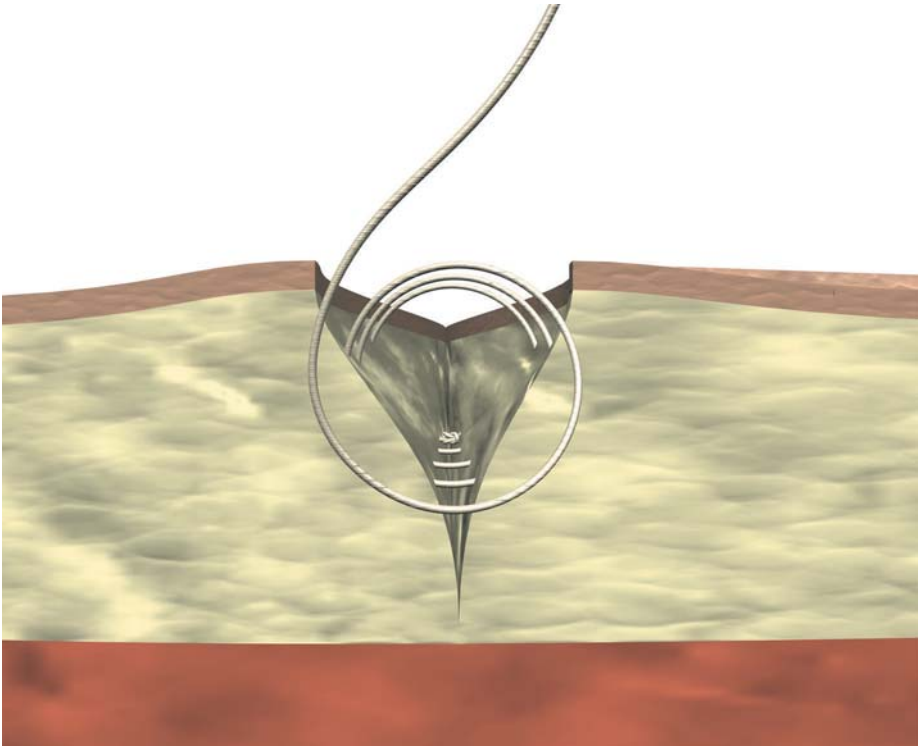
- Short-term absorbable multifilaments

Alternatively, in cases where the wound is subjected to high tension, other sutures can be used, such as:

- Mid-term absorbable multifilaments
- Mid-term absorbable monofilaments

My notes:

Continuous subcutaneous suture

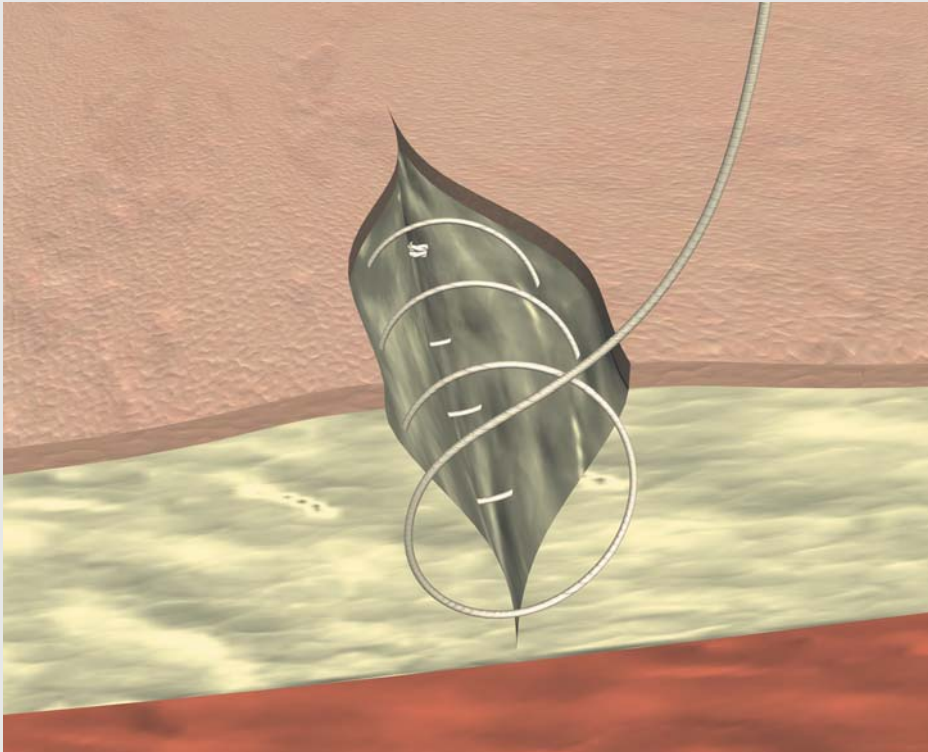


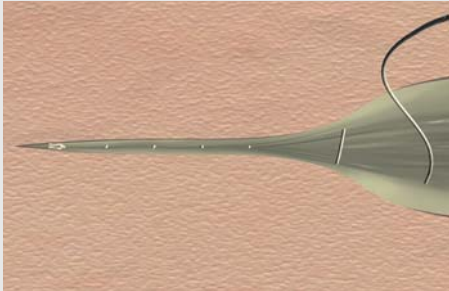
Continuous subcutaneous suture

This is an alternative to the simple subcutaneous stitches. Amongst its advantages is that continuous techniques are more resistant to simple stitching. In addition, continuous suturing can be

performed in a faster way than simple stitches.

A disadvantage of this technique, as for all running sutures is the risk of wound dehiscence in case of suture breakage.





Top view

This suturing technique will obtain optimal results when performed with:

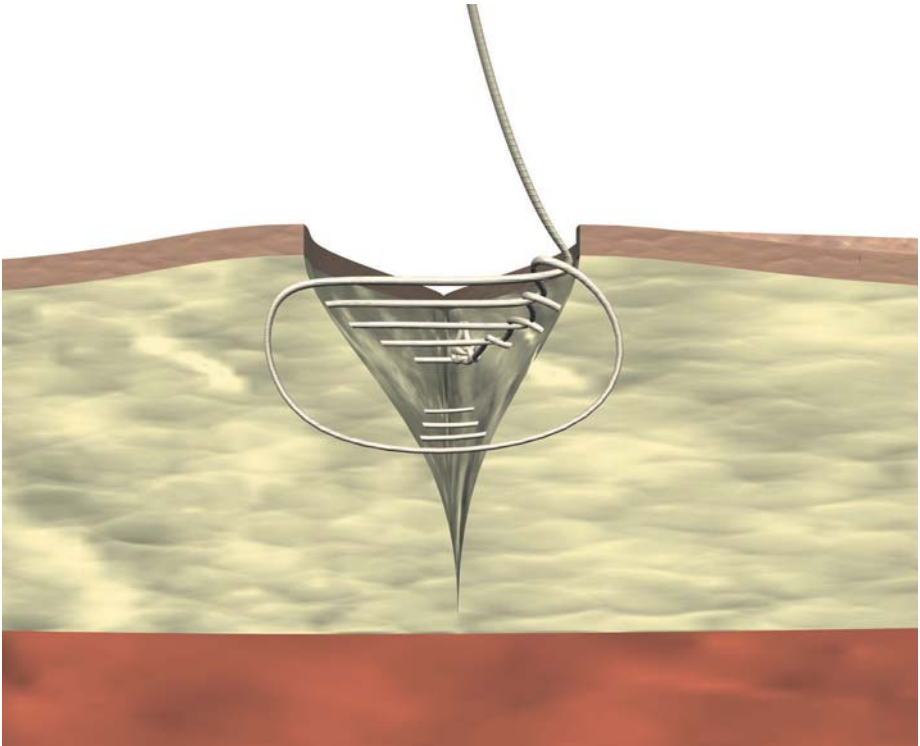
- Short-term absorbable multifilaments

Alternatively, in cases where the wound is subjected to high tension, other sutures can be used, such as:

- Mid-term absorbable multifilaments
- Mid-term absorbable monofilaments

My notes:

Continuous subcutaneous interlaced suture



Continuous subcutaneous interlaced suture

This suture is performed as a variation of a continuous subcutaneous suture.

The interlaced suturing technique will provide extra resistance and will retain most of the tension, making it possible to perform a tension-free skin suture.

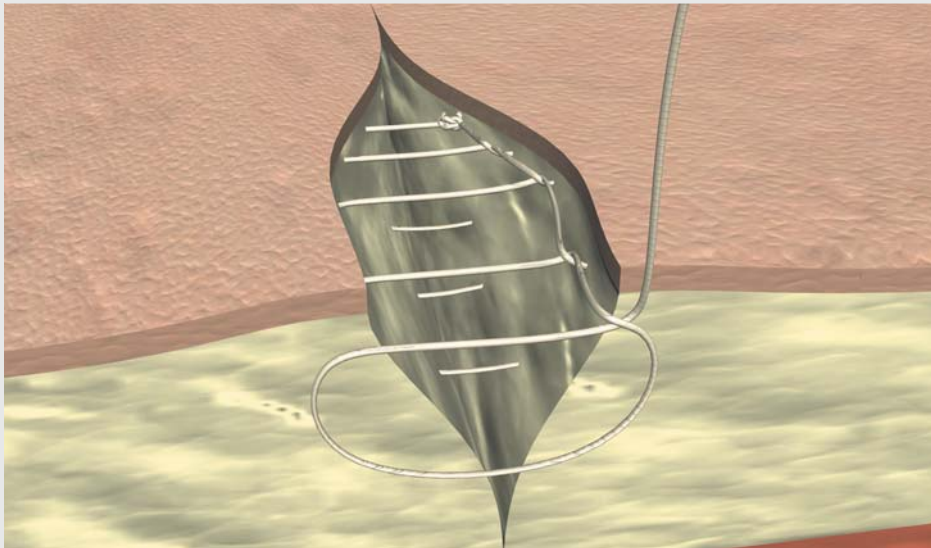
The interlaced suture acts as an anti-slippage suture. The higher friction provided by the threads at each passage provides a stronger hold while suturing and ensures that one stitch will not loosen while performing the next passage.

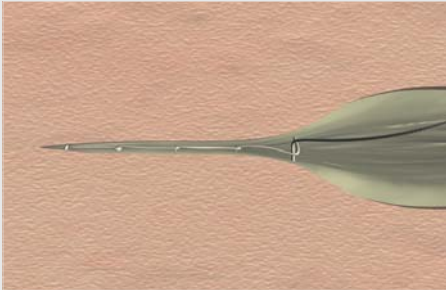
Use of monofilament sutures is recommended, as they present a smoother surface that allows the surgeon to pull

after each passage in order to tighten the part that has already been sutured.

This suture is obtained as a normal continuous suture where the needle is passed through the loop as each stitch is performed.

Since this type of sutures has a high tensile strength, it is very useful on wounds under tension or in highly vascularised tissues that require extra haemostasis. The use of this technique on tissues with poor vascularisation is therefore not advisable and should be avoided.





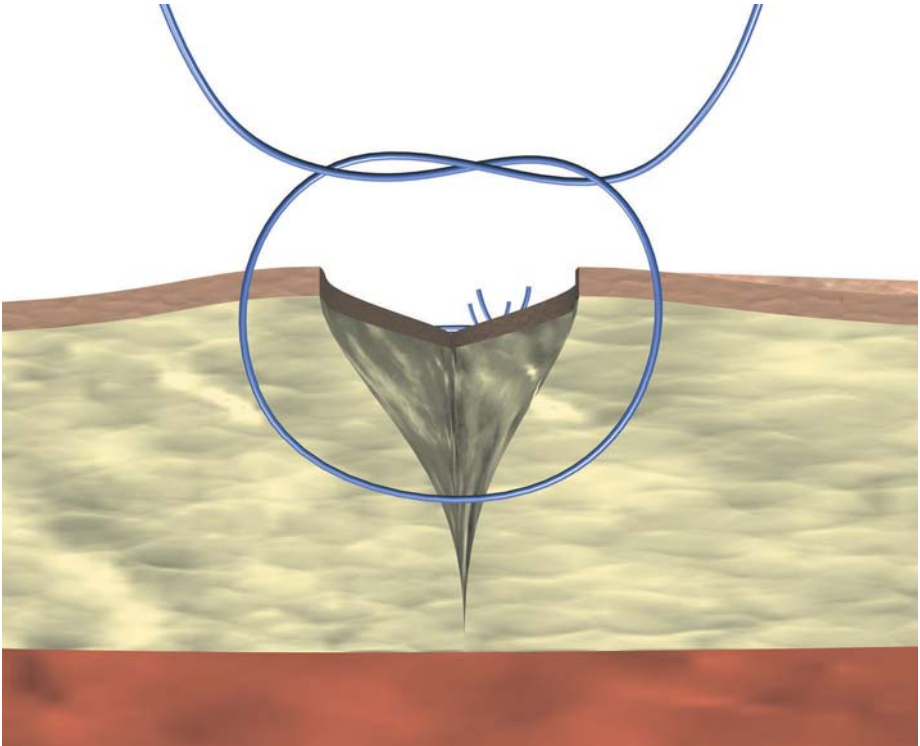
Top view

This suturing technique will obtain optimal results when performed with:

- Mid-term absorbable monofilaments

My notes:

Simple skin suture

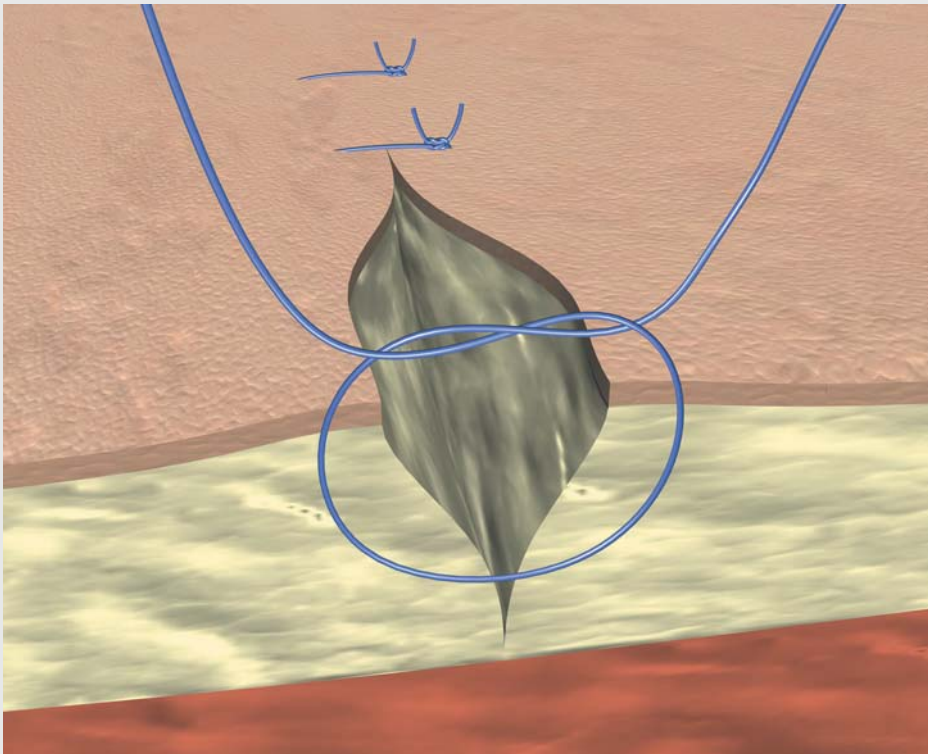


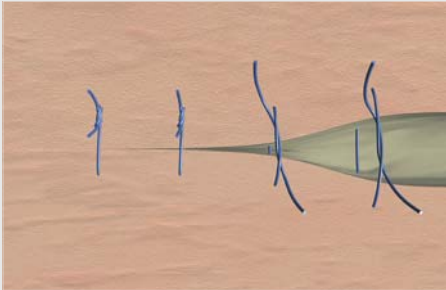
Simple skin suture

This is the most common technique to close a wound. Separated stitches are performed which will hold the wound's edges together.

It is very important that, once performed the first knot, it is positioned on one side so that it does not lie directly on the wound edge and does not disturb the healing process.

These sutures are easy to place, provide great tensile strength and are less likely to compromise blood circulation. On the other hand, they need longer time to be placed and have a higher risk of causing the so-called "railroad track" scars.





Top view

This suturing technique will obtain optimal results when performed with:

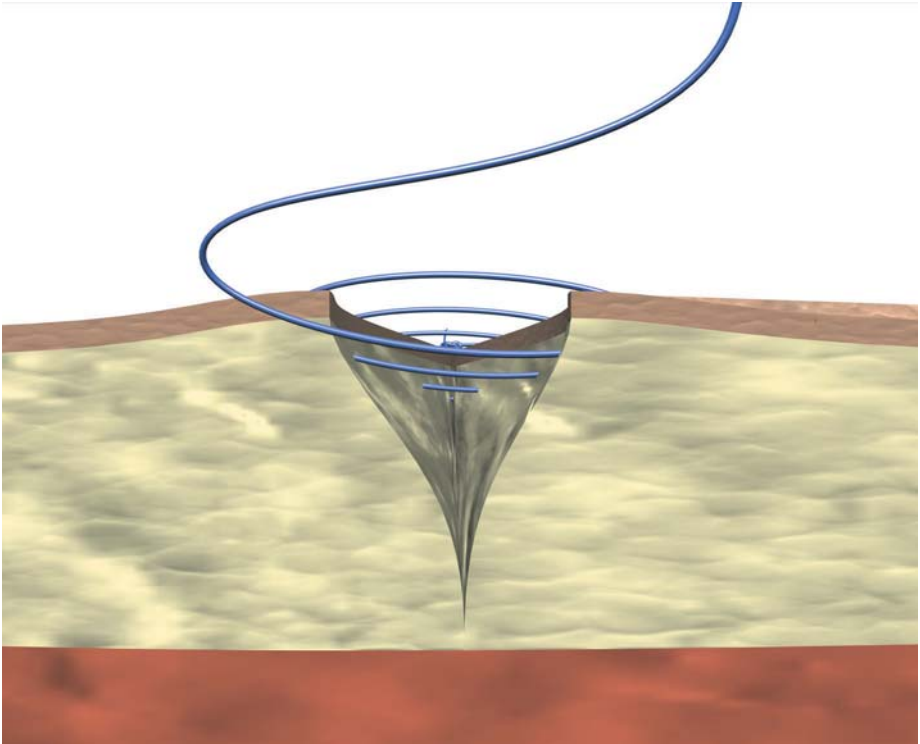
- Non-absorbable monofilaments

Alternatively other sutures can be used, such as:

- Mid-term absorbable monofilaments

My notes:

Continuous skin suture



Continuous skin suture


Also known as "running" suture, this technique is mainly used with tension-free wounds, where deeper sutures have been placed in order to minimize wound tension.

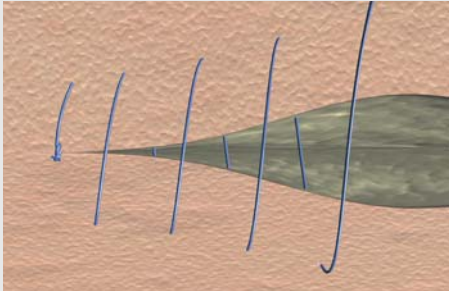
These sutures are considered to cause less scarring due to the fact that less knots are performed. Another advantage is that

they are quite fast to place.

Compared to simple skin sutures, one of the disadvantages of running sutures is that there is a higher risk of dehiscence if the suture breaks.

This technique is commonly used to secure the perimeter of a split- or full-thickness skin graft.





Top view

This suturing technique will obtain optimal results when performed with:

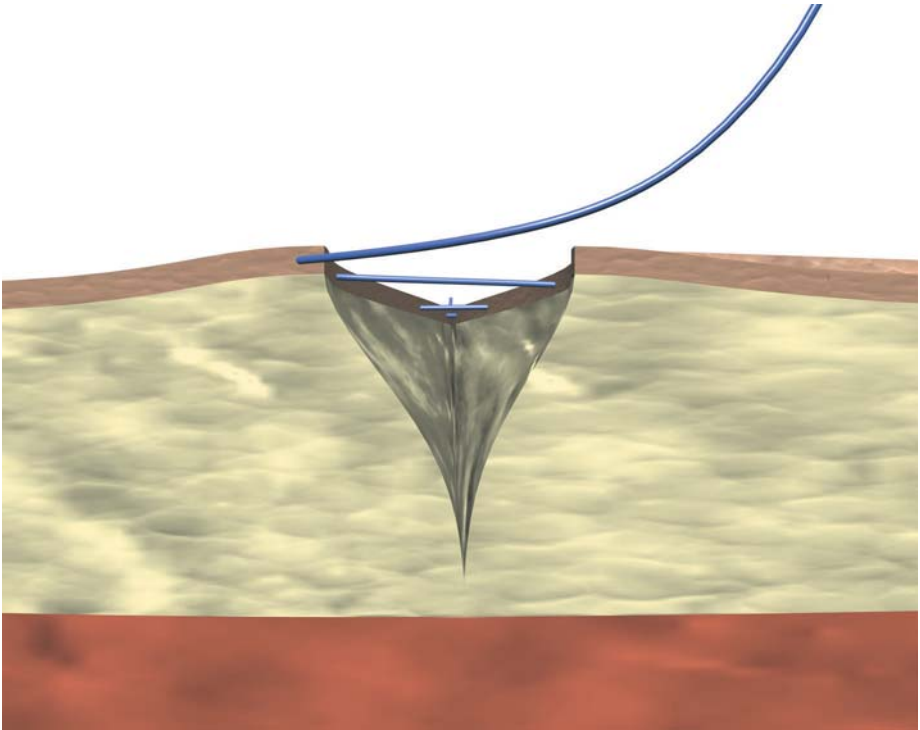
- Non-absorbable monofilaments

Alternatively other sutures can be used, such as:

- Mid-term absorbable monofilaments

My notes:

Continuous intracutaneous non-absorbable suture



Continuous intracutaneous non-absorbable suture

Whenever there is a concern about the aesthetic results of the scar, an intracutaneous suturing technique will be the first choice.

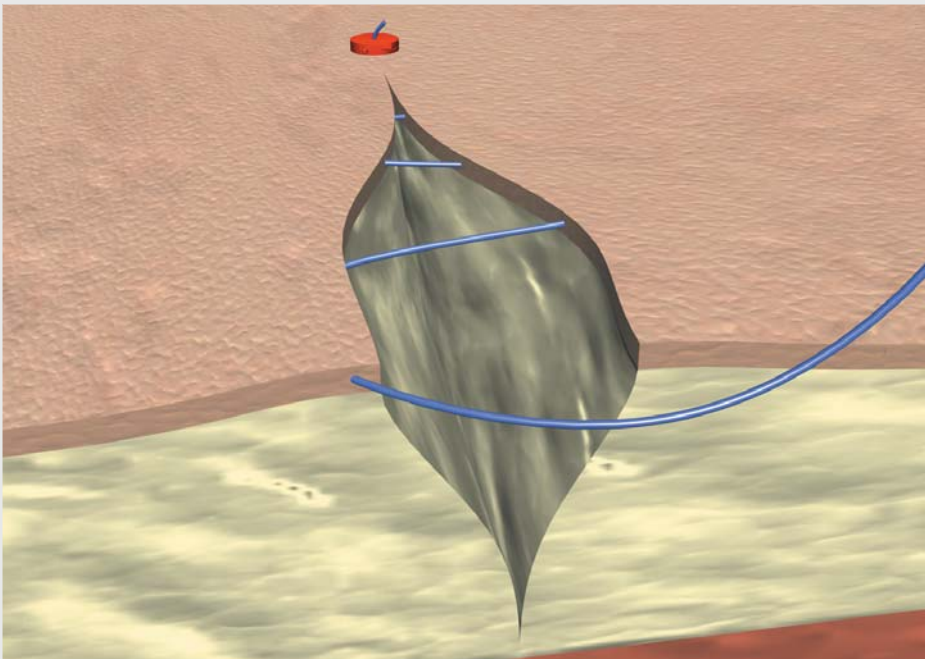
This technique is to be used only in areas with minimal stress, for example in those where tension has been eliminated with deeper sutures.

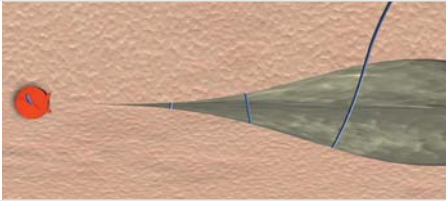
It consists of a monofilament running within the skin, with no parts of the suture coming in and out of the wound sides. Therefore, the amount of tissue to

heal is reduced to a minimum.

Strips should be placed over the wound once the intracutaneous suture has been completed.

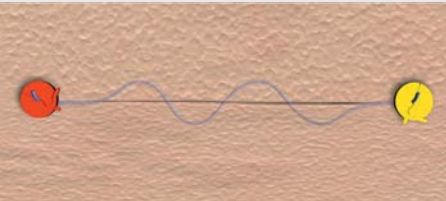
When the healing skin has reached enough strength to keep the wound closed by itself, the suture should be removed by pulling on one of its ends. The smooth surface on the monofilament suture guarantees that it will slide easily through the skin.





This suturing technique will obtain optimal results when performed with:

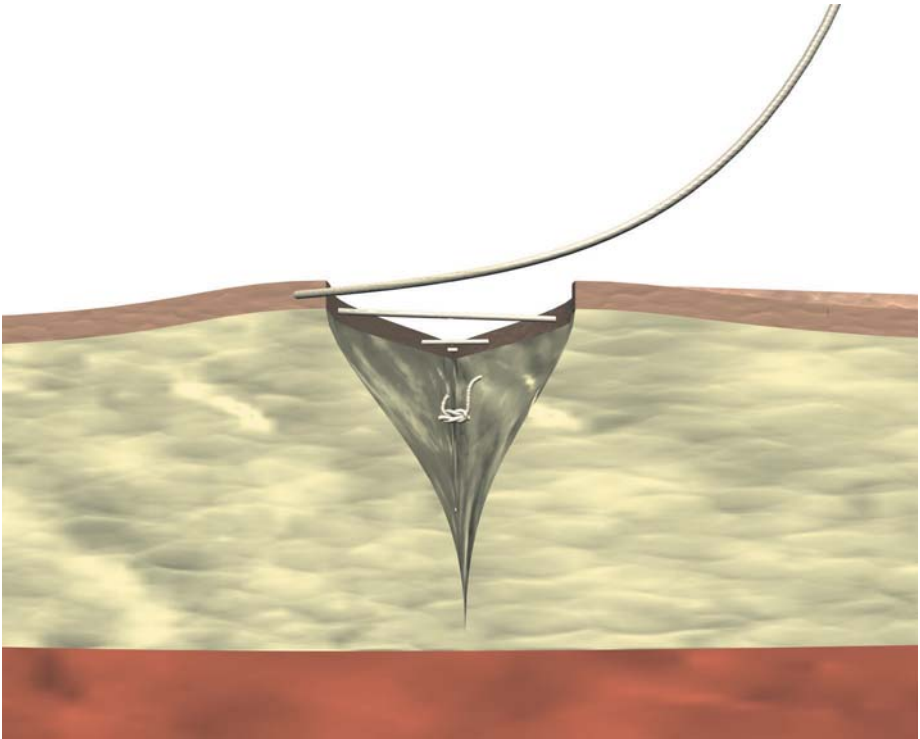
- Non-absorbable monofilaments



Top view

My notes:

Continuous intracutaneous absorbable suture



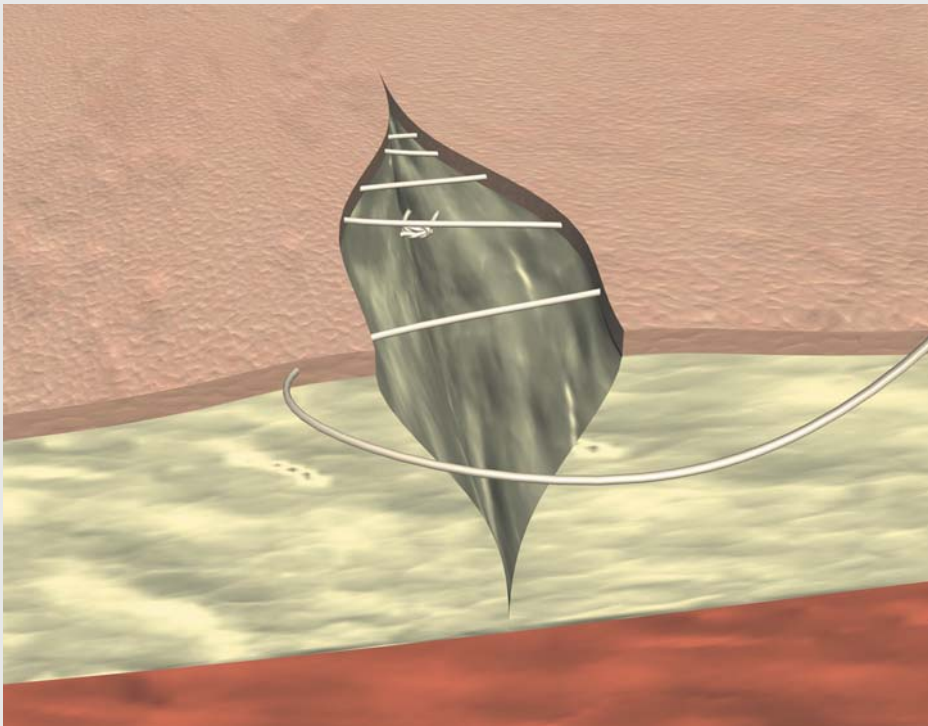
Continuous intracutaneous absorbable suture


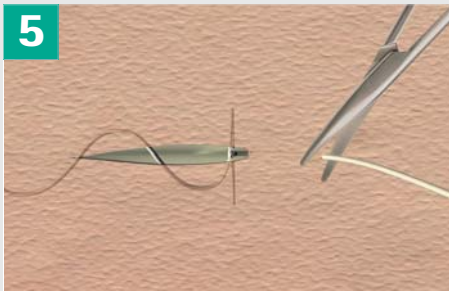


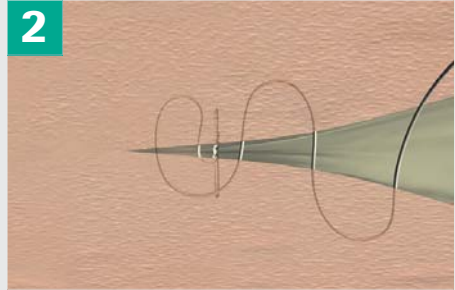

Intracutaneous suturing can also be performed with absorbable sutures, which provide the advantage for the surgeon (and patient) that no second visit needs to be scheduled in order to extract the suture, as it will slowly be degraded by the tissues. However, some surgeons prefer to avoid this whenever possible in order to reduce to a minimum the amount

of foreign material remaining in the wound, as it will only be disturbing the correct healing process.


Strips should be placed over the wound once the intracutaneous suture has been completed.

Remember that intracutaneous suture are to be used only where there is an absence of tension at the skin level.





Continuous intracutaneous absorbable suture



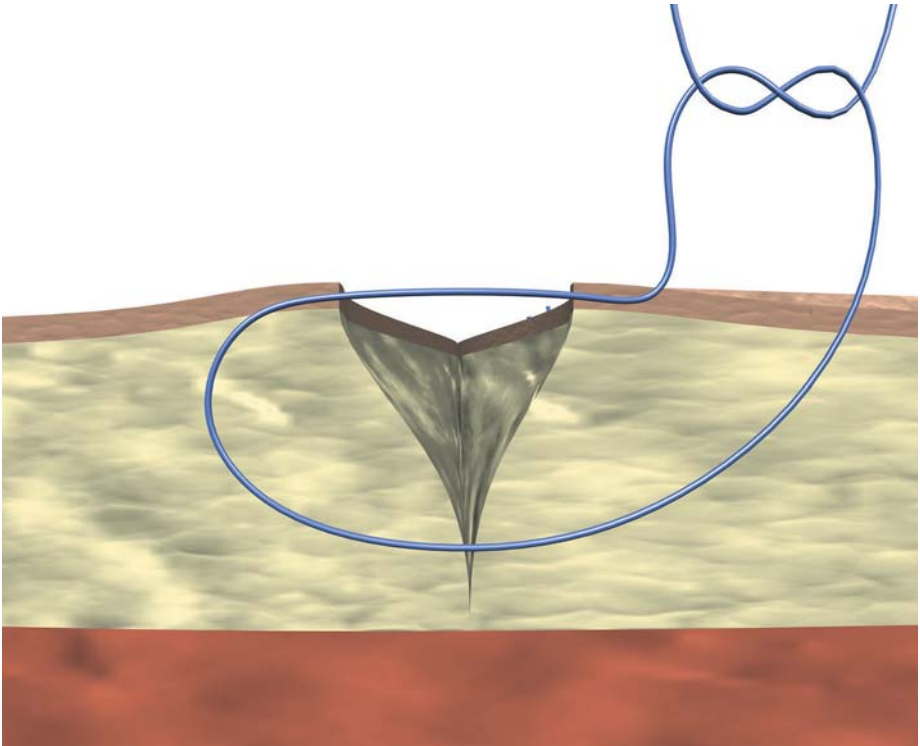
Top view

This suturing technique will obtain optimal results when performed with:

- Mid-term absorbable monofilaments

My notes:

Allgöwer suture



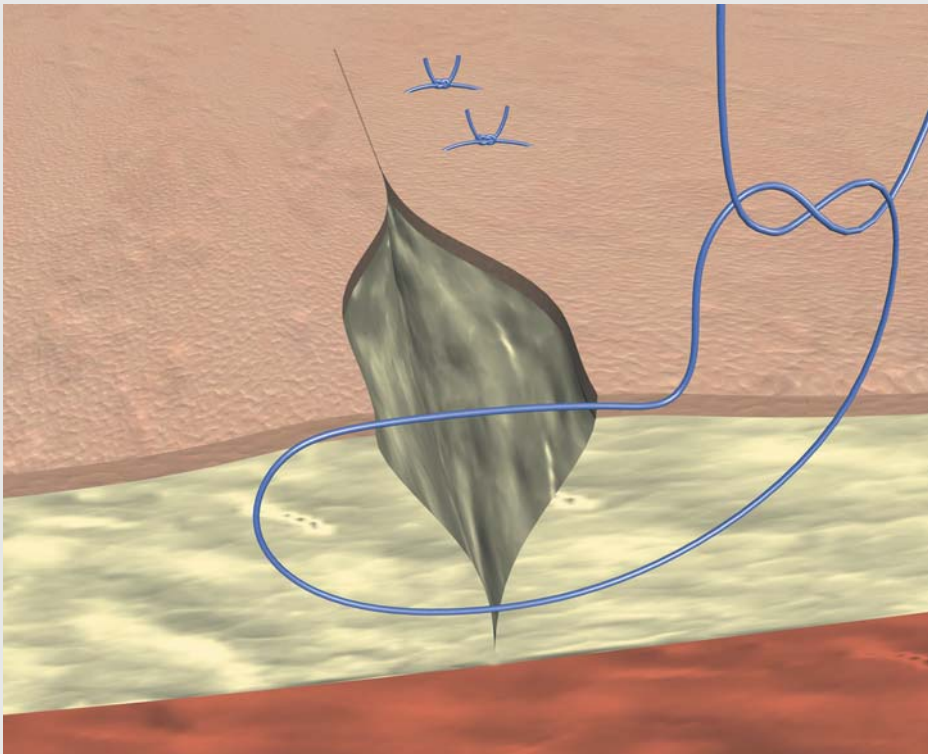
Allgöwer suture

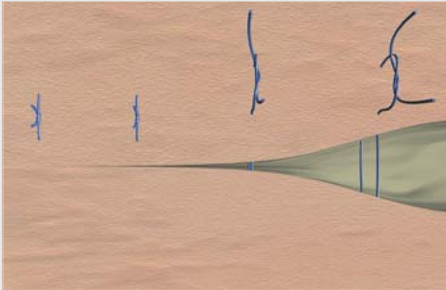
In some cases, the surgeon wants to avoid subcutaneous suturing due to the high risk of infection.

Performing a common skin suturing technique might present a risk of wound dehiscence, and strong sutures will be

needed in order to provide a firm hold. At the same time, this suture will have to close the subcutaneous space.

Keep in mind that this suturing technique should be avoided wherever a good cosmetic result is important.





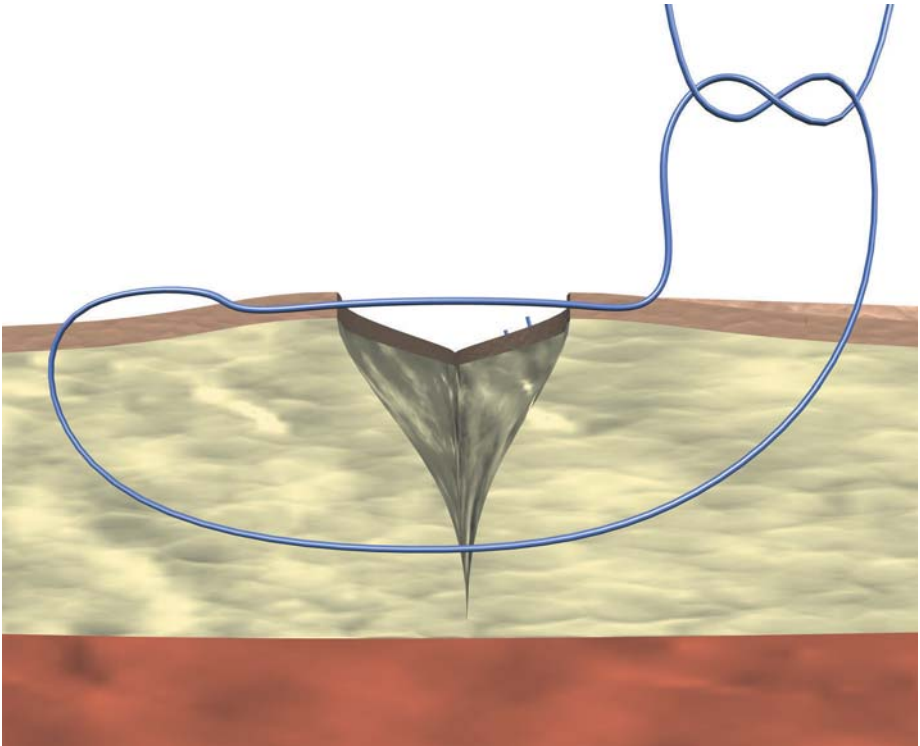
Top view

This suturing technique will obtain optimal results when performed with:

- Non-absorbable monofilaments

My notes:

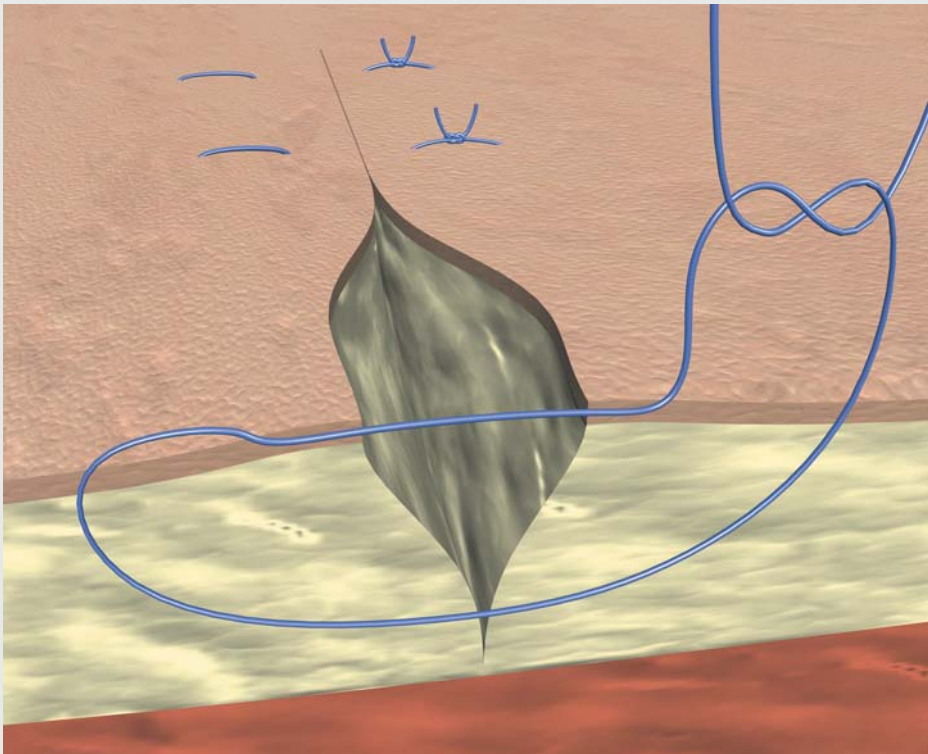
Donati suture

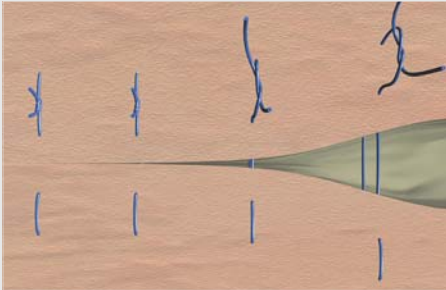


Donati suture

This is a variation of the Allgöwer suture. In this case, the suture crosses the skin at 4 points for each stitch. Therefore,

although providing a firmer hold, the risk of poor aesthetic results is increased.





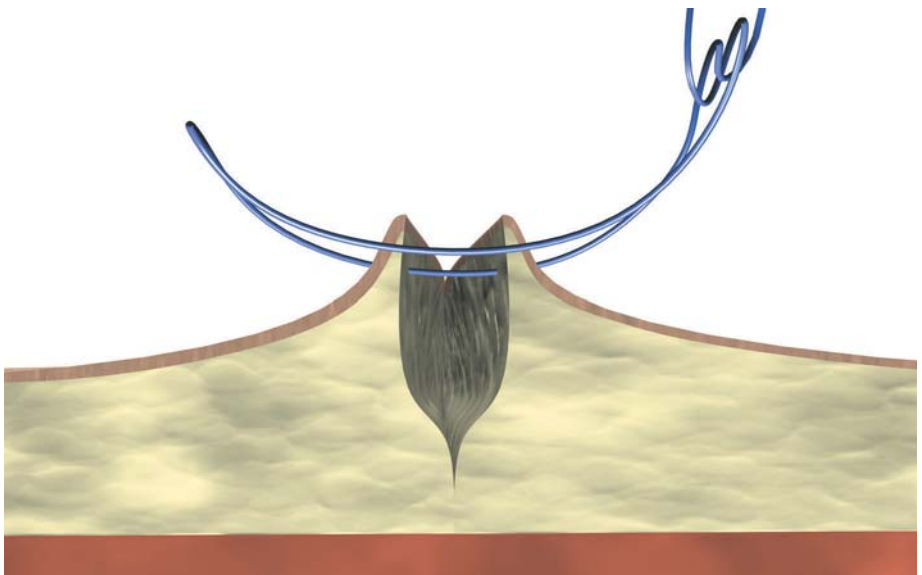
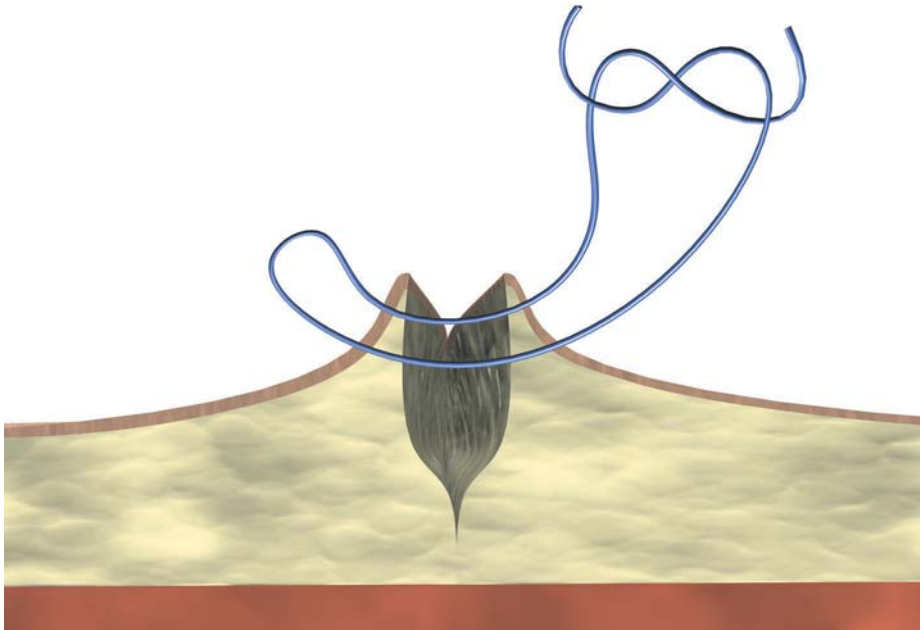
Top view

This suturing technique will obtain optimal results when performed with:

- Non-absorbable monofilaments

My notes:

Mattress suture



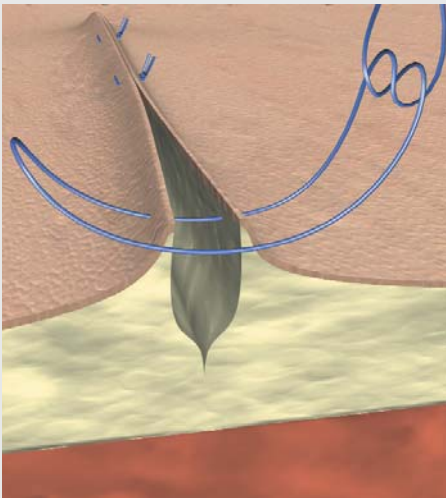
Mattress suture

This suturing technique is used when the wound edges are not close enough to each other to allow tension-free healing. Since a larger amount of tissue is incorporated within the suture passage, tension is well held under the skin edges. One of the disadvantages of this technique is the danger of surface scarring due to increased tension across the wound and also to the fact that the suture enters the skin 4 times on each stitch. However, this effect can be avoided by early removal of the sutures once the tissue has recovered enough strength to be held together without any extra support (5-7 days). If left longer, it is

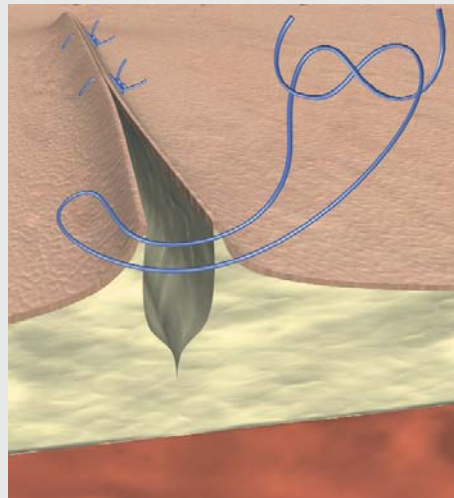
highly recommended to use bolsters in order to minimize suture strangulation of the tissues.

This suturing technique is also used in cases where eversion of the wound edges is desired in order to counteract against the roll-under effect that might happen secondary to tissue contraction during healing.

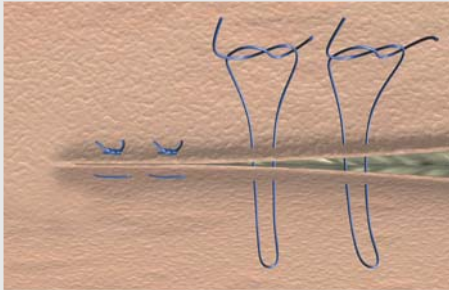
Mattress sutures are specially used in areas where the wound edges tend to invert (e. g. wound on a concave surface). The use of these sutures is limited in areas where a cosmetic result is important. There are two variants of this technique: horizontal and vertical mattress sutures.




Horizontal



Vertical



Top view (horizontal)




Top view (vertical)

This suturing technique will obtain optimal results when performed with:

- Non-absorbable monofilaments

My notes:


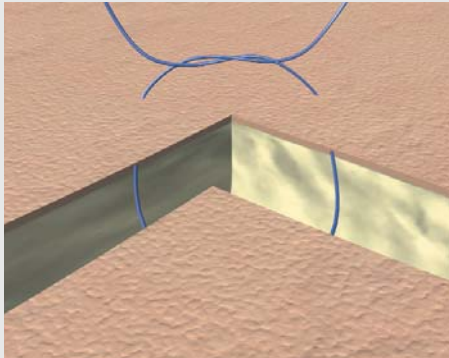
Corner suture




Corner suture

We have to take into account that not always the wound edges will be straight and parallel to each other. In some cases, the edges can be irregular or twisty. Here we present a common case where the wound follows a "corner" pattern. It is of vital importance that this corner is sutured in the right manner in order to avoid necrosis of the tissue.

A simple stitch should never be performed as it carries a high risk of necrosis. Instead, the suturing technique to be used should be an intracutaneous suture knotted on the surface at the outer side of the wound as shown on the pictures below.





Top view




























This suturing technique will obtain optimal results when performed with:

- Non-absorbable monofilaments

My notes:

Complete suture range

Non-absorbable suture material

 Mono-filament Advantage	 Mono-filament Advantage	 Braided	 Braided	 Mono-filament Advantage	 Braided	 Pseudo-mono-filament Advantage	 Braided	 Braided
Optilene®	Premilene®	PremiCron®	Steelex®	Dafilon®	Trelon®	Supramid	Dagrofil®	Silkam®
								
								
Polypropylene and polyethylene non-absorbable	Polypropylene, non-absorbable	Polyester, non-absorbable	Stainless steel, non-absorbable	Polyamide 6/6.6 (dyed blue or undyed), Polyamide 6.6 (dyed black), non-absorbable	Polyamide 6/6, non-absorbable	Polyamide 6/6.6, non-absorbable	Polyester, non-absorbable	Natural silk, non-absorbable
Coating: none	Coating: none	Coating: silicone	Coating: none or polyethylene*	Coating: none	Coating: silicone	Coating: none	Coating: none	Coating: Pure beeswax or re-fined paraffin wax
Structure: monofilament	Structure: monofilament	Structure: braided	Structure: monofilament, twisted	Structure: monofilament	Structure: braided	Structure: monofilament, pseudomonofilament	Structure: braided	Structure: braided
Colour: blue	Colour: blue	Colour: green, white	Colour: metallic	Colour: blue, undyed, black	Colour: black	Colour: black, white	Colour: green, white	Colour: black, white
USP 10/0 to 0 metric 0.2 to 3.5	USP 10/0 to 2 metric 0.2 to 5	USP 6/0 to 5 metric 0.7 to 7	USP 5/0 to 7 metric 1 to 9	USP 11/0 to 2 metric 0.1 to 5	USP 6/0 to 3 metric 0.7 to 6	USP 6/0 to 3 metric 0.7 to 6	USP 6/0 to 6 metric 0.7 to 8	USP 8/0 to 6 metric 0.4 to 8

* Steelex Electrode Set

The product trademarks 'Premilene, PremiCron, Dafilon, Dagrofil, Silkam, Steelex, Monosyn and Safil' are registered trademarks of B. Braun Melsungen AG.

The product trademarks 'Optilene, Trelon, MonoPlus, Monomax and Novosyn' are registered trademarks of Aesculap AG.

Brochure No. B20102

0914/1/4











B | BRAUN
SHARING EXPERTISE

B. Braun Surgical, S.A. | Carretera de Terrassa, 121 | 08191 Rubí | Spain
Phone +34 93 5 86 62 00 | Fax +34 93 6 99 63 30 | www.bbraun.com

Aesculap AG | Am Aesculap-Platz | 78532 Tuttlingen | Germany
Phone +49 7461 95-0 | Fax +49 7461 95-26 00 | www.aesculap.com

Aesculap – a B. Braun company

Absorbable suture material

Mono-filament Advantage	Mono-filament Advantage	Mono-filament Advantage	Mono-filament Advantage	Braided	Braided	Braided
Monosyn® Quick	Monosyn®	MonoPlus®	Monomax	Safil® Quick	Safil®	Novosyn®
						
						
Glyconate, short-term absorbable	Glyconate, mid-term absorbable	Polydioxanone, long-term absorbable	Poly-4 Hydroxybutyrate extra long-term absorbable	Polyglycolic acid, short-term absorbable	Polyglycolic acid, mid-term absorbable	Polyglactin 910, mid-term absorbable
Coating: none	Coating: none	Coating: none	Coating: none	Coating: Glyconate	Coating: Glyconate or uncoated**	Coating: Poly(glycolide-co-l-lactide 30/70) and Calciumstearate
Structure: monofilament	Structure: monofilament	Structure: monofilament	Structure: monofilament	Structure: braided	Structure: braided or monofilament**	Structure: braided
Colour: undyed	Colour: violet, undyed	Colour: violet	Colour: violet	Colour: undyed	Colour: violet, undyed	Colour: violet, undyed
USP 6/0 to 1 metric 0.7 to 4	USP 7/0 to 2 metric 0.5 to 5	USP 7/0 to 2 metric 0.5 to 5	USP 2/0 to 1 metric 3 to 4	USP 7/0 to 2 metric 0.5 to 5	USP 10/0 to 2 metric 0.2 to 5	USP 8/0 to 2 metric 0.4 to 5
Tensile strength retention: 1 Day 100 % 6-7 Days 50 % 10 Days 20-30 %	Tensile strength retention: 1 Day 100 % 14 Days 50 % 21 Days 20 %	Tensile strength retention: 1 Day 100 % 14 Days 90 % 28 Days (≤ USP 4/0) 50 % 35 Days (≥ USP 3/0) 50 %	Tensile strength retention: 1 Day 100 % 14 Days 100 % 28 Days 90 % 42 Days 70 % 84 Days 60 % 112 Days 40 % 140 Days 25 %	Tensile strength retention: 1 Day 100 % 5 Days 50 % 10-14 Days 0 %	Tensile strength retention: 1 Day 100 % 14 Days 60-70 % 21 Days 24-42 %	Tensile strength retention: 1 Day 100 % 14 Days 75 % 21 Days 40-50 % 28 Days 25 %
Mass Absorption: after 56 days	Mass Absorption: after 60 till 90 days	Mass Absorption: after 180 till 210 days	Mass Absorption: between 13 months and more than 36 months	Mass Absorption: after 42 till 56 days	Mass Absorption: after 60 till 90 days	Mass Absorption: after 56 till 70 days

** USP 10/0 and 9/0

All rights reserved. Technical alterations are possible.
This book may be used for no other purposes than
education. No part may be copied or reproduced in
any form. In case of misuse we retain the rights to
take legal actions.

B. Braun Surgical, S.A. | Aesculap | Carretera de Terrassa, 121
08191 Rubí (Barcelona) | Tel. 93 586 62 00 | Fax 93 588 10 96
www.bbraun.es

BBSE-125-02
10/15